

Original Article

Attenuating Potential of *Calendula Officinalis* on Biochemical and Antioxidant Parameters in Hepatotoxic Rats

Pawan Kumar Verma^{1*}, Rajinder Raina¹, Maninder Singh²,
Virendera S. Wazir³ and Pawan Kumar⁴

¹Division of Veterinary Pharmacology and Toxicology,

²Division of Veterinary Public Health and Epidemiology and

³Division of Veterinary Medicine,
Faculty of Veterinary Science and Animal Husbandry,
R.S. Pura, Jammu & Kashmir – 181 102, India

⁴Division of Pathology,
Indian Veterinary Research Institute,
Izatnagar, Bareilly – 243 122 (UP), India

Abstract

Attenuating potential of floral extracts of *Calendula officinalis* on biochemical and antioxidant parameters in blood and hepatic tissue of acetaminophen (APAP) induced hepatotoxicity in wistar rats was determined. Increased ($P < 0.05$) plasma activities of phosphatases, transferases, reduced levels of total proteins and conjugated bilirubin following administration of APAP indicated acute hepatotoxicity. Hepatotoxic rats also exhibited significant reduced levels of total thiols (TTH), reduced glutathione (GSH), total antioxidant status (TAS) and antioxidant enzymes, and increased oxidative stress index (OSI), total oxidant status (TOS) and malondialdehyde (MDA) levels in blood and hepatic tissue. Treatment with ethanolic floral extract restored hepatic blood biomarkers, increased ($P < 0.05$) the levels of TTH, GSH, TAS and antioxidant enzymes, and reduced the levels of MDA, TOS and OSI in blood and hepatic tissue and histopathological alterations in hepatotoxic rats. Study suggested that ethanolic floral extract of *C. officinalis* administrations attenuating the APAP induced oxidative damage in hepatic tissue.

Introduction

Every cell in an organism has to maintain the balance between oxidative and antioxidant status to sustain its vitality. Any change in this balance in either direction results in cell damage (1). Thiols - sulfur

containing compounds - are the most important part of antioxidant defense system in both extracellular and intracellular medium. They consist of low molecular weight (LMW) thiols such as reduced glutathione (GSH), cysteine and protein bound sulfhydryl groups (p-SH). They protect the organism by scavenging reactive oxygen species (ROS) using enzymatic and non-enzymatic mechanism. In blood, alteration in redox state of LMW thiols are being investigated as potential indicator of oxidative stress whereas physiological importance of p-SH is poorly understood (2). A number of clinical and experimental

***Corresponding author :**

Pawan Kumar Verma, PhD, Assistant Professor, Division of Veterinary Pharmacology and Toxicology, Faculty of Veterinary Science and Animal Husbandry, R S Pura, Jammu & Kashmir – 181102, India

(Received on August 1, 2017)

studies have shown that reduced levels of thiols enhanced the drug/toxicant induced oxidative damage in visceral organs (3, 4, 5, 6).

Applications of herbs/phytochemicals for the treatment of various ailments have been used since civilization. *Calendula officinalis* (Family *Compositae*) have high medicinal potential used in folklore system of medicine. Floral extracts of *C. officinalis* have high concentration of polyphenolic compounds (terpenoids and flavonoids) compared to other plant parts (7, 8). Additionally, floral extracts of the plant are rich source of polyunsaturated fatty acids (9), mineral substances (10) and vitamin C (11) contributing to their wide ethnomedicinal potential. Recently, *C. officinalis* extracts have been approved by food and drug administration as GRAS (Generally Recognized as Safe) substance for use in food industry (12). Experimental studies have shown that the administration of polyphenolic compounds reduces the drug/toxicant induced oxidative damage in experimental models either by direct scavenging potential or increased availability of thiols (5, 13, 14, 15). Further, clinical trials have shown that supplementation of flavonoids increases the availability of thiols (GSH, cysteine etc) for providing protection to vital organs from oxidative insults. The cellular mechanism of protection imparted by the flavonoids is still unclear. Liver is most versatile vital visceral organ of mammalian body having a prominent role in synthesis of macromolecules, conversion of endogenous and exogenous substances to harmless and excretable compounds besides homeostasis of internal environment (16). Therefore, the present study was aimed to determine the levels of total thiols and oxidative stress index in blood and hepatic tissue of experimentally induced hepatotoxic rats and its attenuation by administration of floral extracts of *Calendula officinalis*.

Materials and Methods

Collection and preparation of extracts:

The flowers of *C. officinalis* bloom in early spring and were collected from different parts of Jammu (India) after taxonomic identification by Taxonomist, Department of Botany, University of Jammu (AU-

2875). During summer months flowering declines and stops during peak hot weather of summer. Sufficient fresh flowers were collected and air-dried in shade (temperature not exceeding 40°C) for 3-4 weeks in divisional laboratory. Air dried flowers were pre-crushed and later pulverized into fine powder using electric blender. Aqueous extract was prepared by soaking dry powder in 1:10 ratio in distilled water for 72 h with intermittent shaking. After 72 h of soaking the content was filtered through filter paper (0.45 µm) and filtrate was concentrated under reduced pressure using rotatory evaporator (10-15 rpm at 50-55°C). Ethanolic extract was prepared by using ethyl alcohol in extract container of soxhlet apparatus according to standard method (17). The dried aqueous and ethanolic floral extracts of *C. officinalis* were stored in air tight containers. The extracts were reconstituted in 0.1 % carboxy methylcellulose (CMC) for oral gavage in wistar rats.

Induction of hepatotoxicity in experimental animals:

Adult wistar rats between (175-200 g) of either sex were procured from Indian Institute of Integrative Medicine, Jammu. Animals were provided standard pelleted ration and *ad-libitum* drinking water under standard managemental conditions. The experimental protocol was dully approved by Institutional Animal Ethics Committee (IAEC) vide letter no FVSc/C-11/2456-68. Single high oral dose of APAP (3 g/kg b wt in 0.1% CMC) was used for induction of acute hepatotoxicity in experimental animals (18). Forty two rats were randomly divided into 7 groups with 6 rats in each. The control (Group I) received only 1 ml/rat/day vehicle (0.1% CMC) for 7 days, Group II received vehicle (0.1% CMC) 1 ml/rat/day followed by a single oral dose of APAP (3 g/kg b wt) (Sigma-Aldrich, USA) on 5th day of administration. Group III was fed with standard drug silymarin (100 mg/kg b wt) (Sigma-Aldrich, USA) orally daily for 7 days and received APAP at earlier mentioned dose rate on 5th day of administration. Group IV and V received aqueous and ethanolic extract (300 mg/kg b wt) of *C. officinalis* orally daily for 7 days, respectively. Group VI and VII received aqueous and ethanolic extracts similar to group IV and V, respectively; in addition APAP was administered on the 5th day. The dose of plant extract was determined on the basis of reported toxic dose and pharmacological activities

of the plant extract (3, 5, 11, 19).

Collection and processing of samples:

3-4ml blood samples were collected in sterilized tubes containing heparin directly from heart of anesthetized rats whereas hepatic tissue samples were collected after sacrificing rats on 8th day (24 hr after 7th dose administration). The blood samples were centrifuged at 4000 rpm for 10 min to separate plasma. Plasma was collected in glass vials followed by storage at -4°C pending the estimation of biochemical parameters and oxidative stress parameters on the same day. Hepatic tissue (1 g) were collected in 10 ml ice cold phosphate buffer solution (0.5 M, pH-7.4) for stress parameters and formal saline (10%) for histopathological studies. Tissue samples were homogenized using teflon coated homogenizer at 1000 rpm for 5-7 min at refrigeration temperature and 10% tissue homogenate was prepared for determining various stress biomarkers.

Assaying of antioxidant parameters:

Total antioxidant status (TAS) in plasma and hepatic tissue homogenate was determined and expressed as mM of ascorbic acid equivalents by using 2, 2'-azino-bis (3-ethylbenzothiazoline 6-sulphonate) (20). Similarly, TOS level was measured using automated method developed by Ereli (21) and results expressed in terms of micro mol H_2O_2 Equiv/ L. The percent ratio of TOS to TAS level was used for determination of oxidative stress index (OSI) in plasma and tissue homogenate (22). Total thiols (TTH) and malondialdehyde (MDA) levels in blood and tissue homogenate was determined as per the standard methods (23, 24). The other antioxidant enzymes viz. catalase (CAT) (25), superoxide dismutase (SOD) (26), glutathione peroxidase (GPx) (27) and glutathione-S-transferase (GST) (28) were determined in blood and hepatic tissue by standard methods. Reduced glutathione (GSH) in blood was determined using standard protocol (29).

Assaying of blood biochemical parameters:

Blood biochemical parameters like total plasma proteins, albumins total and direct bilirubin and

activities of AST, ALT (aspartate and alanine aminotransferases), GGT (gamma glutamyl transferase), ALP (alkaline phosphatase) and LDH (lactate dehydrogenase) in different treatment groups were determined by standard kits (Transasia Bio-Medicals Ltd, India) using Chemistry Analyzer (CHEM-7, ERBA, Mannheim).

Histopathological studies:

The histopathological studies were carried out according to standard protocol. The formalin (10%) fixed hepatic tissues were embedded in paraffin, sectioned and stained with hematoxylin and eosin (H & E) followed by examination under a light microscope for histopathological assessment.

Statistical analysis:

The antioxidant parameters are presented as Mean \pm Standard error. The results were analyzed statistically by analysis of variance (ANOVA) in completely randomized design (CRD) using Duncan Multiple Range post hoc Test at 5% level of significance.

Results

Blood biochemical parameters:

Significantly increased ($P<0.05$) levels of hepatic biomarkers viz. ALT, AST, GGT, ALP and LDH following APAP administration as compared to control animals witnessed hepatotoxicity. APAP treatment along with aqueous extract of *C. officinalis* normalized the GGT, ALP and LDH activities whereas activities of AST and ALT were higher ($P<0.05$) than the control group; however, ethanolic extract of *C. officinalis* with APAP restored the levels of all hepatic biomarkers (Table I). Alterations in the plasma levels of proteins and bilirubin profiles in various treatment groups in wistar rats are presented in Table II. On administering a single high dose of APAP, there was decline ($P<0.05$) in total and indirect bilirubin while the level of direct bilirubin was higher ($P<0.05$) than the control group. The treatments of aqueous or ethanolic floral extract of *C. officinalis* with APAP restored the levels of total, direct and indirect

TABLE I: Attenuating potential of aqueous and ethanolic floral extracts of *C. officinalis* administrations on plasma hepatic biomarkers in hepatotoxic rats.

Groups	ALT	AST	GGT	ALP	LDH
Control	51.20±2.90 ^a	87.37±4.18 ^a	3.35±0.35 ^{ab}	215.63±18.09 ^a	250.40±14.13 ^a
Acetaminophen (APAP)	209.23±9.33 ^d	301.10±27.54 ^c	8.11±0.34 ^c	440.48±20.70 ^b	520.52±32.72 ^c
Silymarin + APAP	54.81±2.19 ^{ab}	84.07±6.85 ^a	4.59±0.40 ^b	267.88±10.67 ^a	233.88±17.79 ^{ab}
Aqueous extract	80.29±5.61 ^c	159.03±8.78 ^b	4.60±0.67 ^b	434.58±35.94 ^b	304.85±31.53 ^b
Ethanolic extract	98.03±4.28 ^c	192.58±13.08 ^b	2.89±0.24 ^a	427.20±38.07 ^b	233.42±21.86 ^b
Aqueous extract + APAP	69.72±4.40 ^{bc}	198.43±12.96 ^b	4.21±0.30 ^b	301.52±49.75 ^a	291.33±27.62 ^{ab}
Ethanolic extract + APAP	57.42±5.12 ^{ab}	82.80±5.10 ^a	3.46±0.40 ^{ab}	229.83±14.70 ^a	276.20±31.42 ^{ab}

Values are given as Mean±SE of 6 animals unless otherwise stated. Values having different superscripts (a, b, c & d) in a column are statistically different from one another at 5% level of significance. Values of AST & ALT (aspartate & alanine aminotransferase), GGT (gamma glutamyl transferase), ALP (alkaline phosphatase) and LDH (lactate dehydrogenase) are expressed in U/L.

TABLE II: Attenuating potential of aqueous and ethanolic floral extracts of *C. officinalis* administrations on plasma proteins and bilirubin profiles in hepatotoxic rats.

Groups	TB	DB	IB	TPP	Albumin
Control	0.547±0.093 ^a	0.142±0.019 ^b	0.405±0.095 ^a	7.47±0.26 ^d	3.59±0.13 ^b
Acetaminophen (APAP)	0.950±0.116 ^c	0.095±0.007 ^a	0.855±0.112 ^b	5.43±0.24 ^a	2.50±0.16 ^a
Silymarin + APAP	0.713±0.055 ^b	0.103±0.012 ^b	0.610±0.047 ^a	6.87±0.31 ^{cd}	4.05±0.23 ^b
Aqueous extract	0.513±0.084 ^a	0.080±0.005 ^b	0.433±0.084 ^a	6.58±0.26 ^{bc}	4.11±0.20 ^b
Ethanolic extract	0.517±0.073 ^a	0.097±0.009 ^b	0.420±0.074 ^a	7.02±0.25 ^{cd}	3.96±0.20 ^b
Aqueous extract + APAP	0.647±0.104 ^{ab}	0.087±0.011 ^b	0.560±0.097 ^{ab}	5.84±0.23 ^{ab}	3.76±0.24 ^b
Ethanolic extract + APAP	0.918±0.117 ^c	0.095±0.010 ^b	0.823±0.109 ^{ab}	6.46±0.30 ^{bc}	3.96±0.17 ^b

Values are given as Mean±SE of 6 animals unless otherwise stated. Values having different superscripts (a, b, c & d) in a column are statistically different from one another at 5% level of significance. Values of TB (total bilirubin) DB (direct bilirubin) IB (indirect bilirubin) are expressed in mg/dITPP (Total plasma proteins) and albumin are expressed in g/dl.

bilirubin. Regarding the effects on the total plasma proteins, albumin and globulin, single oral administration of APAP decreased ($P<0.05$) all of these. Administration of silymarin to APAP restored total plasma proteins and albumin whereas levels of globulin were lower ($P<0.05$) than control group. Administration with either aqueous or ethanolic floral extract of *C. officinalis* in APAP administered rats failed to restore the levels of total plasma proteins while levels of albumin were restored.

Antioxidant system in blood:

There was a decline ($P<0.05$) in the levels of TAS, TTH, and GSH, and an increase in TOS and OSI on APAP treatment. The administration of silymarin with APAP restored TOS, OSI and GSH levels except that of TAS which was lower ($P<0.05$) than control group. Pre and post exposure of aqueous floral extract of *C. officinalis* in APAP exposed rats improved levels of TAS, TTH and GSH but decreased TOS ($P<0.05$) level. Treatment with ethanolic extract, however,

increased TAS and TTH levels and restored those of GSH (Fig. 1). Activities of CAT, SOD, GPx and GST dropped ($P<0.05$) in APAP exposed rats compared to control. Pre-treatment with silymarin restored the activities of CAT, GPx, GST and SOD compared to APAP treated group. The treatments of aqueous extract with APAP were not able to normalize the levels of CAT, SOD, GPx and GST. In contrast to aqueous extract, the ethanolic extract with APAP normalized CAT, GPx and GST, and not that of SOD (Fig. 2).

Antioxidant system in hepatic tissue:

Levels of different non-enzymatic components and enzymatic parameters of antioxidant system in hepatic tissue in various groups are presented in Table III and Fig. 3 respectively. Significant ($P<0.05$) reduction in TAS and TTH, and an increase in TOS and OSI were observed in APAP treatment. Silymarin treatment with APAP restored TOS and TTH but not of OSI which may be due to reduced ($P<0.05$) level

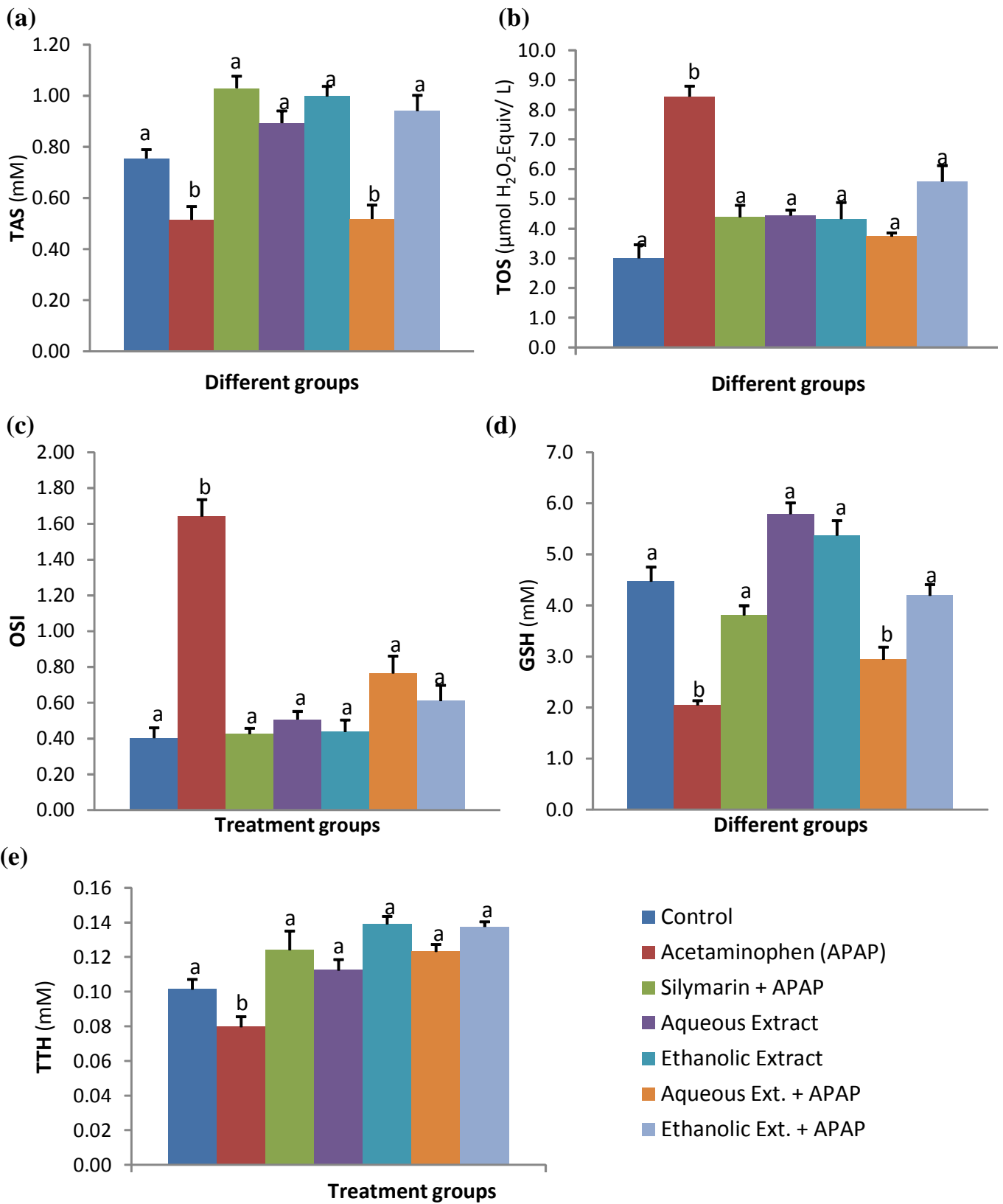


Fig. 1: Attenuating potential of aqueous and ethanollic floral extracts of *C. officinalis* administrations on levels of TAS (a), TOS (b), OSI, (c), GSH (d) and TTH (e) in blood of hepatotoxic rats.

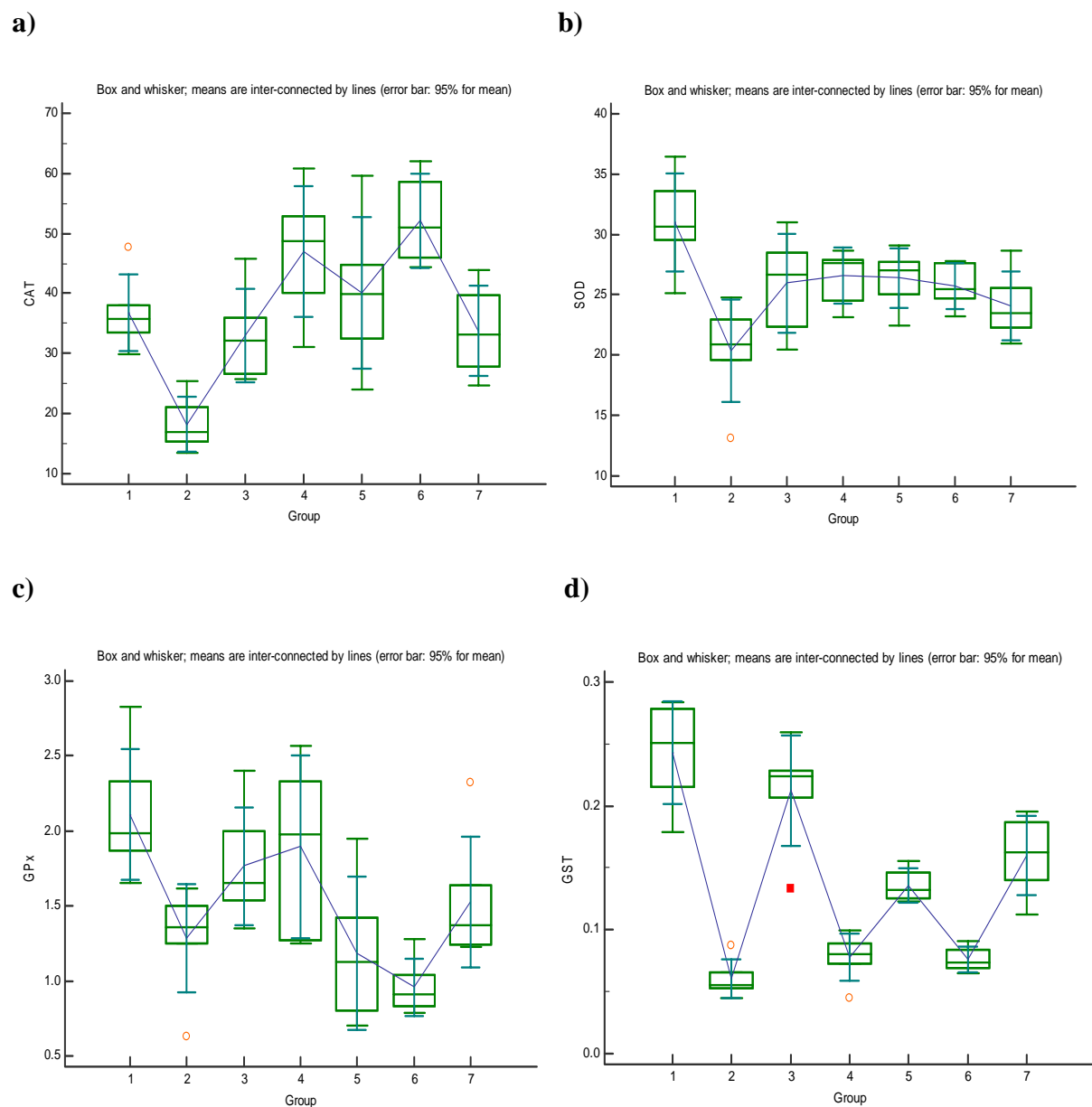


Fig. 2 : Attenuating potential of aqueous and ethanolic floral extract of *C. officinalis* administrations on erythrocytes activities of (a) CAT ($\mu\text{mol H}_2\text{O}_2$ decomposed/min/mg of Hb), (b) SOD (Unit/ mg of Hb), (c) GPx (Unit/ mg of Hb) and (d) GST ($\mu\text{mol of CDNB conjugate formed/ min/ mg of Hb}$) in hepatotoxic rats. (Group 1 – control, Group 2 – acetaminophen (APAP) treatment, Group 3 – silymarin with APAP, Group 4 and 5 – aqueous and ethanolic extract alone, Group 6 and 7 – aqueous and ethanolic extract along with APAP).

TABLE III : Attenuating potential of aqueous and ethanolic floral extracts of *C. officinalis* administrations on the levels of TAS, TOS, OSI and TTH in hepatic tissue of hepatotoxic rats.

Groups	TAS (mM)	TOS ($\mu\text{mol H}_2\text{O}_2$ Equiv/L)	OSI	TTH (mM)
Control	10.88 \pm 0.36 ^b	30.79 \pm 3.26 ^b	0.287 \pm 0.033 ^b	5.22 \pm 0.17 ^d
Acetaminophen (APAP)	5.33 \pm 0.29 ^a	50.94 \pm 4.46 ^a	0.964 \pm 0.083 ^a	2.78 \pm 0.25 ^a
Silymarin + APAP	6.00 \pm 0.24 ^a	32.74 \pm 2.28 ^b	0.550 \pm 0.046 ^{cd}	5.23 \pm 0.31 ^d
Aqueous extract	15.26 \pm 1.01 ^c	47.63 \pm 6.49 ^{cd}	0.327 \pm 0.061 ^b	3.90 \pm 0.25 ^{bc}
Ethanolic extract	9.75 \pm 1.37 ^b	56.63 \pm 5.94 ^d	0.637 \pm 0.084 ^d	4.79 \pm 0.34 ^d
Aqueous extract + APAP	4.47 \pm 0.46 ^a	27.16 \pm 1.78 ^b	0.643 \pm 0.089 ^d	3.20 \pm 0.32 ^{ab}
Ethanolic extract + APAP	9.57 \pm 0.63 ^b	38.37 \pm 3.88 ^{bc}	0.429 \pm 0.066 ^{bc}	4.63 \pm 0.26 ^{cd}

Values are given as Mean \pm SE of 6 animals unless otherwise stated. Values having different superscripts (a, b, c & d) in a column are statistically different from one another at 5% level of significance.

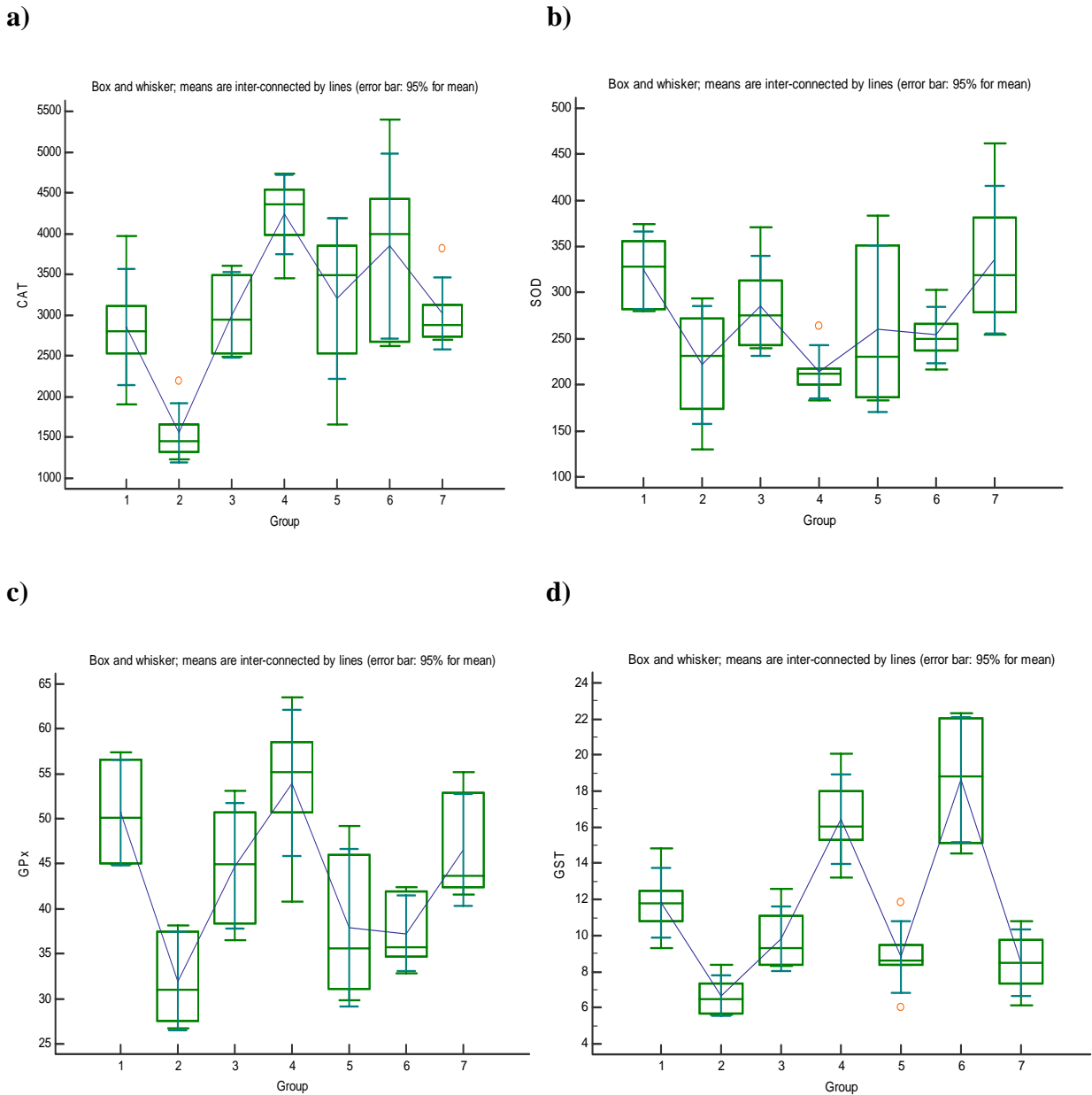


Fig. 3: Attenuating potential of aqueous and ethanolic floral extracts of *C. officinalis* administrations on hepatic tissue activities of (a) CAT ($\mu\text{mol H}_2\text{O}_2$ decomposed/ min/ g of tissue), (b) SOD (Unit/ g of tissue), (c) GPx (Unit/g of tissue) and (d) GST (μmol of CDNB conjugate formed/min/g of tissue) in hepatotoxic rats. (Group 1 – control, Group 2 – acetaminophen (APAP) treatment, Group 3 – silymarin with APAP, Group 4 and 5 – aqueous and ethanolic extract alone, Group 6 and 7 – aqueous and ethanolic extract along with APAP).

of TAS. The treatments of aqueous floral extract of *C. officinalis* with APAP failed to normalize the levels TOS, OSI and TTH while ethanolic extract did all of these. Similarly, single administration of APAP reduced ($P < 0.05$) the hepatic CAT, SOD, GPx and GST activities compared to control group. Silymarin treatment with APAP restored all of these while aqueous extract treatments with APAP didn't. The ethanolic extract treatments with APAP restored the

activities of CAT, SOD and GPx but not of GST, and was lower to the control group in APAP treated animals.

APAP administration increases cellular membrane damage as indicated significantly ($P < 0.05$) increased membrane lipid peroxidation i.e. MDA levels in both erythrocytes and hepatic tissue. Administration of silymarin/ aqueous extract/ ethanolic extract with

APAP declined ($P < 0.05$) the levels of MDA in blood, although the values were higher ($P < 0.05$) than control group. Similarly administration of silymarin/aqueous extract/ethanolic extracts of *C. officinalis* following APAP lowered its values in hepatic tissue, although the levels were higher than the control group (Fig. 4). Correlation analysis of oxidant and antioxidant system of blood and hepatic tissue were presented in Table IV. Correlation analysis of oxidant and antioxidant parameters revealed, that significant negative correlation between MDA level and TAS was also observed with SOD, GPx and GST. Contrary to blood, hepatic tissue showed that MDA levels was significantly negative correlated with levels of TTH, TOS, OSI, SOD and GPx.

Histopathological alterations in hepatic tissue:

Microscopic examination of hepatic tissue on APAP

administration showed infiltration of mononuclear cells, small to large areas of hepatic necrosis which were characterized by cytoplasmic dissolution and fragmentation of nuclei and membranes as compared to normal hepatic tissue (Fig. 5 A & B). Treatment with either aqueous or ethanolic extract of *C. officinalis* followed by APAP revealed presence of mild infiltration of mononuclear cells around bile duct and blood vessels at certain areas. Sinusoids were dilated around the central vein in hepatic tissue. The alterations showed the histopathological slide on treatment of either aqueous or ethanolic floral extracts of *C. officinalis* followed by APAP administration (Fig. 5 C & D). Intensity of structural alterations in microphotographs revealed that ethanolic floral extract have more protective potential than the aqueous extract of *C. officinalis*.

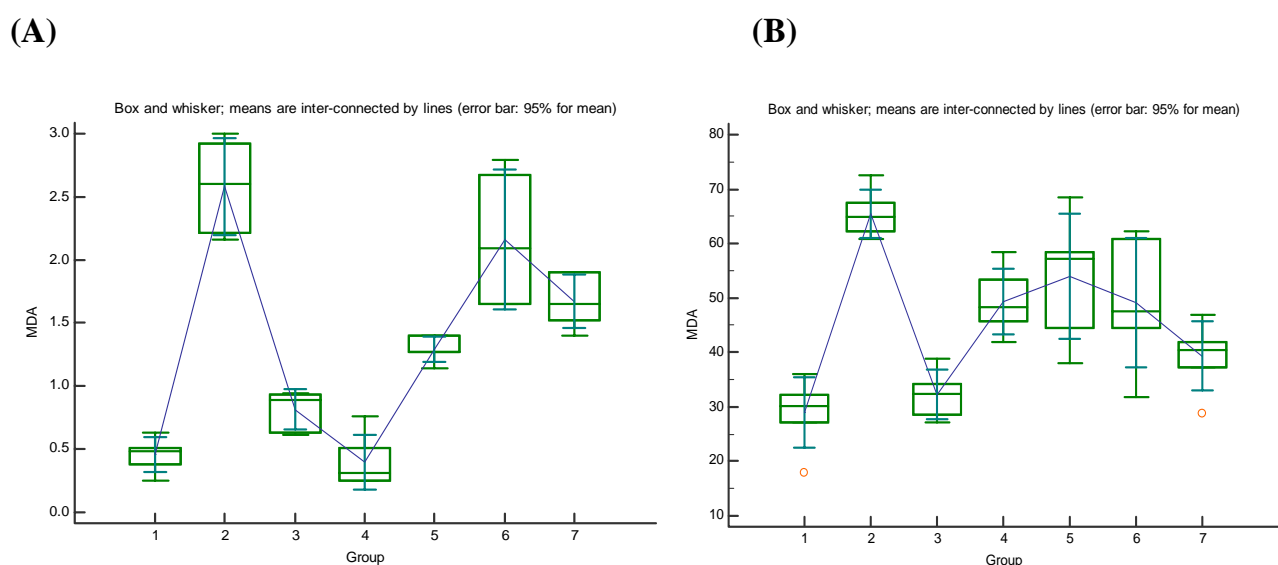


Fig. 4 : Attenuating potential of aqueous and ethanolic floral extracts of *C. officinalis* administrations on malondialdehyde (MDA) levels in (A) erythrocyte lysate (nmole of MDA formed/ml/h) and (B) hepatic tissue (nmole of MDA formed/g/h) of hepatotoxic rats. (Group 1 – control, Group 2 – acetaminophen (APAP) treatment, Group 3 – silymarin with APAP, Group 4 and 5 – aqueous and ethanolic extract alone, Group 6 and 7 – aqueous and ethanolic extract along with APAP).

TABLE IV : Spearman correlation between oxidant and antioxidant parameters with cellular damage indicator (MDA) in blood and hepatic tissue of hepatotoxic rats.

(n = 42)	TAS	TOS	OSI	TTH	CAT	SOD	GPx	GST
MDA (Blood)	-0.445*	0.231	0.011	-0.053	-0.215	-0.466*	-0.635*	-0.472*
MDA (Hepatic tissue)	-0.037	0.460*	-0.414*	-0.608*	-0.113	-0.554*	-0.525*	-0.183

*Statistically different at 5% level of significance.

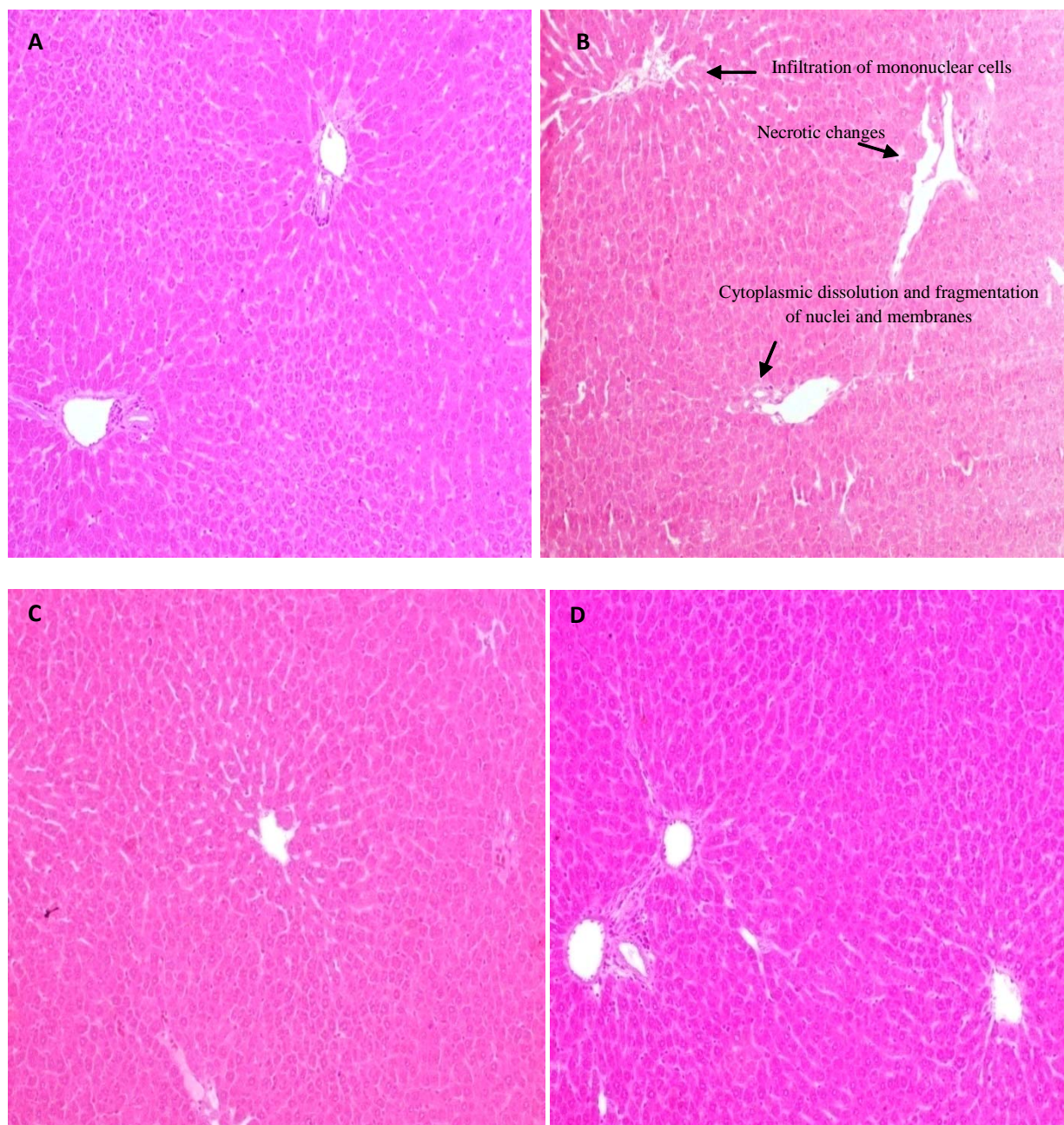


Fig. 5: Representative histomicrograph of hepatic tissue (H&E stained, 10x) of control animals (A), alterations in hepatic tissue (B) on acetaminophen administration and its attenuation by aqueous (C) or ethanolic (D) floral extract of *C. officinalis* administrations.

Discussion

Chronic hepatic diseases stand as one of the foremost health troubles worldwide with liver cirrhosis and drug induced liver injury leading to death in western and developing countries. A better understanding of the pathophysiology of drug induced

toxicity and the mechanisms involved in hepatotoxicity are critical to improve human health and public awareness of potentially harmful toxicants (16, 30). Activities of AST, ALT, GGT, ALP, LDH and levels of plasma proteins and bilirubin profile (conjugated and unconjugated) are commonly used plasma hepatic biomarkers to determine the extent of hepatic damage in mammalian species. GGT

activity is more sensitive but less specific hepatic damage indicator than ALP and AST. Rapid increase in activity of plasma GGT is indicative of either obstructive jaundice or acute hepatocellular damage. AST is present in high concentration in liver and to a lesser extent in cardiac, skeletal muscle, kidney, brain, pancreas, lung etc. ALT is mainly present in liver cells and is a relatively specific indicator of hepatocellular damage as compared to AST. It is released early in liver damage and remains elevated for weeks. ALP, a zinc containing enzyme, is found in liver, bile duct, small intestines, bones, lungs and kidney. ALP is also a critical enzyme in biological process and is responsible for detoxification, metabolism and biosynthesis of macromolecules for different biological functions. Elevated levels of these markers in blood indicate damage to liver and other organs (31). Single high dose oral administration of APAP increased plasma activities of AST, ALT, GGT, ALP and LDH and bilirubin levels (total and indirect), and decreased direct bilirubin indicating acute hepatic damage in wistar rats. Bilirubin (unconjugated) is a yellow pigment produced when heme is catabolized. Hepatocytes render bilirubin water-soluble and therefore easily excretable by conjugating it with glucuronic acid (conjugated bilirubin) prior to secreting it into bile. Exposure of hepatotoxicant results in the increased levels of unconjugated bilirubin probably due to inability of hepatocytes for conjugation process. Increased total and direct bilirubin following APAP exposure in present study may result from production of more bilirubin than the liver can process and/or damage/obstruction of excretory ducts of the liver impairs its ability to excrete normal amounts of bilirubin. Serum bilirubin is considered to be one of the true tests of liver functions since it reflects the ability of the liver to take-up and process bilirubin into bile. Our findings are consistent with the findings of Xu *et al.* (32) and Hussein *et al.* (33) who reported *in vitro* hepatoprotective effect of ethanolic flower extract *C. officinalis* (by preventing the leakage of hepatocellular enzymes from hepatocytes cell lines) as well as *in vivo* studies in APAP induced hepatotoxicity in experimental animals (34, 35).

Increased ROS formation as a consequence of increased metabolic activities has been postulated

to be the major determinant of organ functions. Excessive intermediates metabolites (NAPQI) and other reactive molecules viz. superoxide, hydrogen peroxide, hydroxyl radicals, etc formation on administration of APAP may lead to imbalance in antioxidant system. Normally NAPQI is rapidly conjugated with reduced GSH and is excreted as the cysteine conjugate or the corresponding mercapturic acid. During overdosing excess production of NAPQI are responsible for the depletion of GSH levels in hepatocytes leading to interaction of NAPQI to other macromolecules especially cysteine groups on different intracellular (enzymatic and structural) and transporter proteins leading to hepatocellular necrosis (16). Decreased GSH and increased free radicals production within cells can also oxidize macromolecules such as DNA, proteins, and lipids which may cause cell dysfunction and death (36). Increased levels of MDA in both erythrocytes and hepatocytes results in reduced cellular antioxidant defense to counter the free radicals generated due to APAP metabolism. Investigation of various components of antioxidant system viz. total antioxidant status and total oxidant status revealed that increased oxidant formation and reduced antioxidant defense of erythrocyte and hepatocytes both are responsible for the hepatotoxicity on APAP exposure. Further, reduced levels of TTH in blood and tissue, and reduced GSH levels in blood may have been responsible for the reduced TAS of the cell. TAS of the intracellular medium depends on the availability of sulfhydryl group (-SH group) and other antioxidant defense enzymes viz. CAT, SOD, GPx and GST. Reduction in enzymatic activities and availability of -SH group in hepatotoxic rats may be either due to its excessive utilization or decreased synthesis/recycling. The reduced level of TAS increased the free radicals/ROS interaction with macromolecules like membrane lipid and cellular proteins leading to the oxidative damage. The increased MDA levels may be due to significant reduction of enzymatic viz. CAT, SOD, GPx, and GST levels and non-enzymatic components (-SH, GSH, etc) of antioxidant system which are primarily responsible for the scavenging these free radicals/ROS (36, 37). Observations showed toxic insults from the APAP overdosing are primarily due to imbalance of antioxidant status i.e. drug-induced

oxidative damage in the hepatic tissue and erythrocytes.

Attenuating potential of *C. officinalis*:

Dietary modifications and chemoprevention are considerably effective approaches against oxidative stress and are the focus of research these days. Various herbal formulations in the market are also claiming efficacy against hepatic disorders and are based on their age old use in folklore system of medicine. Because of diverse nature of cellular damage during disorders, protective strategies depend on the mechanism of hepatic damage (38). Protective mechanism of various herbal extracts in hepatic damage is uncertain and many theories have been proposed (39). Floral extracts of *C. officinalis* - rich source of polyphenolic compounds – have high reducing power, antioxidant potential and scavenging potential for the superoxide, peroxide, hydroxy and free radicals (8, 40, 41). The level of conjugated bilirubin was normalized in hepatotoxic rats which may be due to increased availability of glucuronic acid for conjugation by the polyphenolic compounds present in the extract (42). Administration of floral extracts in hepatotoxic rats restored plasma levels of hepatic biomarkers i.e. phosphatases, transferases and dehydrogenases possibly because of reduced leakage by maintaining hepatocytes membrane integrity. Oral administration of floral extracts in hepatotoxic rats showed significant reduction in membrane lipid peroxidation i.e. MDA levels of blood as well as hepatic tissue. The reduction in MDA levels may be either due to reduced levels of free radicals concentration (increased direct scavenging by polyphenolic compounds) or decreased production of NAPQI and other free radicals by inhibiting cytochrome P450 enzymes responsible for APAP metabolism (43).

In various experimental and clinical studies protective effects of polyphenolic compounds have been attributed to free radicals scavenging potential or by boosting and antioxidant defense of the mammals. The direct scavenging of free radicals/ROS is a well studied phenomenon; however, mechanism underlying

the boosting of an antioxidant system is still a researchable issue. Most of the researchers hypothesizes that increased level of thiols (protein and non-proteins) is one of the primary mechanisms for enhancing antioxidant system of animals (44, 45). Restoration of GSH level in the present study may be due to increased activity of glutamate cysteine ligase (GCL), a rate limiting enzyme for GSH synthesis. Various studies have shown that flavonoids present in the plant extract increase the GCL activities and restore GSH level (44, 45). Similarly increased levels of GSH in hepatotoxic rats were also reported on repeated administration of floral extract of *C. officinalis* (34). Observations indicated that ethanolic extracts have more hepatoprotective potential than the aqueous extract of *C. officinalis*. The ethanolic floral extract contains significantly high carotenoids primarily as compared to aqueous floral extract of *C. officinalis*. (8, 9, 40). These observations further signify the protective role of polyphenolic compounds (carotenoids, terpenoids, etc) present in the plant extracts. On administration of floral extract in hepatotoxic rats, activities of CAT, SOD, GST and GPx were normalised. This may be due to restoration of GSH level which acts as cofactor for CAT, GPx and GST which further act in scavenging xenobiotics for restoring cellular redox (46). The reduction in structural alterations in histopathological observations in floral extract administered hepatotoxic rats also indicated the hepatoprotective potential of ethanolic floral extract of *C. officinalis*.

Conclusions

Observations of present study suggested that single high oral dose of APAP administration induced acute hepatotoxicity due to imbalance in antioxidant system of hepatic tissue. Correlation analysis of oxidant and antioxidant parameters revealed the negative ($p < 0.05$) correlation between MDA levels and TAS levels in blood whereas in hepatic tissue MDA levels were negatively correlated with TTH and TOS. Study showed that ethanolic floral extract of *C. officinalis* increased the levels of TTH and GSH which may be responsible for the hepato-protection during APAP induced oxidative damage.

Acknowledgements

Authors thank to the Dean, Faculty of Veterinary

Sciences and Animal Husbandry, R S Pura, Jammu for providing necessary facilities for conducting the research.

Authors declare there are no conflicts of interest.

References

1. Circu ML, Aw TY. Reactive oxygen species, cellular redox systems, and apoptosis. *Free Radic Biol Med* 2010; 48: 749–762.
2. Jones DP, Carlson JL, Mody VC, Cai J, Lynn MJ, Sternberg P. Redox state of glutathione in human plasma. *Free Radic Biol Med* 2000; 28: 625–635.
3. Behling EB, Sendão MC, Francescato HD, Antunes LM, Costa RS, Bianchi Mde L. Comparative study of multiple dosage of quercetin against cisplatin-induced nephrotoxicity and oxidative stress in rat kidneys. *Pharmacol Rep* 2006; 58: 526–532.
4. Verma PK, Raina R, Sultana M, Singh M, Kumar P. Total antioxidant and oxidant status of plasma and renal tissue of cisplatin-induced nephrotoxic rats: protection by floral extracts of *Calendula officinalis* Linn. *Ren Fail* 2016; 38: 142–150.
5. Verma PK, Raina R, Sultana M, Singh M. Modulatory effects of *Alstonia scholaris* on biochemical and antioxidant parameters in experimentally induced hepatotoxicity in wistar rats. *Res J Med Plants* 2015; 9: 406–416.
6. Raina R, Baba NA, Verma PK, Sultana M, Singh M. Hepatotoxicity induced by subchronic exposure of fluoride and chlorpyrifos in wistar rats: Mitigating effect of ascorbic acid. *Biol Trace Elem Res* 2015; 166: 157–162.
7. Raal A, Kirsipuu K. Total flavonoid content in varieties of *Calendula officinalis* L. originating from different countries and cultivated in Estonia. *Nat Prod Res* 2011; 25: 658–662.
8. Verma PK, Raina R, Sultana M. Phytochemical constituents and antioxidant potential in floral extracts of *Calendula officinalis* Linn. *World J Pharmaceut Res* 2014; 3: 2067–2083.
9. Neukiron H, D'Ambrosio M, Dovia J, Guerriero A. Simultaneous quantitative determination of eight triterpenoid monoesters from flowers of 10 Varieties of *Calendula officinalis* L and characterization of a new triterpenoid monoester. *Phytochem Analysis* 2004; 15: 30–35.
10. Naguib NY, Khalil MY, El Sherbeny SE. A comparative study on the productivity and chemical constituents of various sources and species of *Calendula* plants as affected by two foliar fertilizers. *J Applied Sci Res* 2005; 1: 176–189.
11. Silva EJR, Gonçalves ES, Aguiar F, Evencio LB, Lyra MMA, Coelho MCOC, Fraga MCCA, Wanderley AG. Toxicological studies on hydroalcohol extract of *Calendula officinalis* L. *Phytother Res* 2007; 21: 332–336.
12. Lagarto A, Bueno V, Guerra I, Valdés O, Vega Y, Torres L. Acute and subchronic oral toxicities of *Calendula officinalis* extract in Wistar rats. *Exp Toxicol Pathol* 2011; 63: 387–391.
13. Saller R, Meier R, Brignoli R. The use of silymarin in the treatment of liver diseases. *Drugs* 2001; 61: 2035–2063.
14. Francescato HD, Coimbra TM, Costa RS, Bianchi Mde L. Protective effect of quercetin on the evolution of cisplatin-induced acute tubular necrosis. *Kidney Blood Press Res* 2004; 27: 148–158.
15. Abd-ellah MF, Aly H, Mokhlis H, Abdel-aziz AH. Quercetin attenuates di-(2-ethylhexyl) phthalate-induced testicular toxicity in adult rats. *Hum Exp Toxicol* 2016; 35: 232–243.
16. Nelson SD. Molecular mechanisms of the hepatotoxicity caused by acetaminophen. *Semin Liver Dis* 1990; 10(4): 267–278.
17. Harborne JB. *Phytochemical Methods A Guide to Modern Techniques of Plant Analysis*. Springer Science & Business Media; 1998.
18. Visen PK, Shukla B, Patnaik GK, Dhawan BN. Andrographolide protects rat hepatocytes against paracetamol-induced damage. *J Ethnopharmacol* 1993; 40: 131–136.
19. Re TA, Mooney D, Antignac E, et al. Application of the threshold of toxicological concern approach for the safety evaluation of calendula flower (*Calendula officinalis*) petals and extracts used in cosmetic and personal care products. *Food Chem Toxicol* 2009; 47: 1246–1254.
20. Re R, Pellegrini N, Proteggente A, Pannala A, Yang M, Rice-evans C. Antioxidant activity applying an improved ABTS radical cation decolorization assay. *Free Radic Biol Med* 1999; 26: 1231–1237.
21. Erel O. A new automated colorimetric method for measuring total oxidant status. *Clin Biochem* 2005; 38: 1103–1111.
22. Aycicek A, Erel O, Kocyigit A, Selek S, Demirkol MR. Breast milk provides better antioxidant power than does formula. *Nutrition* 2006; 22: 616–619.
23. Motchnik AP, Frei B, Ames NB. Measurement of antioxidants in human blood plasma, Protein thiols. In: Packer L, eds. *Oxygen radicals in biological systems, Methods in Enzymology*. California, Academic Press, 1994; 234(D): 273–274.
24. Shafiq-ur-rehman. Lead-induced regional lipid peroxidation in brain. *Toxicol Lett* 1984; 21: 333–337.
25. Aebi HE. Catalase, In: Bergmeyer HU, eds. *Methods of Enzymatic Analysis*, New York, Academic Press; 1983; 276–286.
26. Marklund S, Marklund G. Involvement of superoxide anion radical in autoxidation of pyrogallol and a convenient assay for superoxide dismutase. *Eur J Biochem* 1974; 47: 469–474.
27. Hafeman DG, Sunde RA, Hoekstra WG. Effect of dietary selenium on erythrocyte and liver glutathione peroxidase in the rat. *J Nutrition* 1974; 104: 580–587.
28. Habig WH, Pabst MJ, Jakoby WB. Gultathione-S-transferases: The first enzymatic step in mercapturic acid formation. *J Biol Chem* 1974; 249: 7130–7139.

29. Beutler E. Red cell metabolism, a manual of biochemical methods 2nd Edn, pp. 67-69, Grune Stratton, New York. 1975.
30. Currie RA, Bombail V, Oliver JD, et al. Gene ontology mapping as an unbiased method for identifying molecular pathways and processes affected by toxicant exposure: application to acute effects caused by the rodent non-genotoxic carcinogen diethylhexylphthalate. *Toxicol Sci* 2005; 86: 453-469.
31. Forbes S, Vig P, Poulsom R, Thomas H, Alison M. Hepatic stem cells. *J Pathol* 2002; 197: 510-518.
32. Xu D, Wu Y, Liao ZX, Wang H. Protective effect of verapamil on multiple hepatotoxic factors-induced liver fibrosis in rats. *Pharmacol Res* 2007; 55: 280-286.
33. Hussain MS, El-Tawil OS, Yassin NH, Abdou KA. The protective effect of *Morus alba* and *Calendula officinalis* plant extracts on carbon tetrachloride induced hepatotoxicity in isolated rat hepatocytes. *J Am Sci* 2010; 6: 719-734.
34. Preethi KC, Kuttan R. Hepato and reno protective action of *Calendula officinalis* L. flower extract. *Indian J Exp Biol* 2009; 47: 163-168.
35. Rusu MA, Tamas M, Puica C, Roman I, Sabadas M. The hepatoprotective action of ten herbal extracts in CCl₄ intoxicated liver. *Phytother Res* 2005; 19: 744-749.
36. James LP, Mayeux PR, Hinson JA. Acetaminophen-induced hepatotoxicity. *Drug Metab Dispos* 2003; 31: 1499-1506.
37. Sallie R, Tredger JM, William R. Drug and liver biopharmaceutical. *Drug Disposition* 1991; 12: 251-259.
38. Farghaly HS, Hussein M.A. 2010. Protective effect of curcumin against paracetamol induced liver damage. *Aust J Basic Appl Sci* 2010; 4: 4266-4274.
39. Suresh KSV, Sujatha C, Syamala J, Nagasudha B, Mishra SH. Protective effect of root extract of *Operculina turpethum* L. against paracetamol-induced hepatotoxicity in rats. *Ind J Pharmaceut Sci* 2006; 68: 32-35.
40. Liu J, Zhou Q, Wang S. Evaluation of chemical enhancement on phytoremediation effect of Cd-contaminated soils with *Calendula officinalis* L. *Int J Phytoremediation* 2010; 12: 503-515.
41. Fonseca YM, Catini CD, Vicentini FT, Cardoso JC, Cavalcanti de albuquerque junior RL, Vieira fonseca MJ. Efficacy of marigold extract-loaded formulations against UV-induced oxidative stress. *J Pharm Sci* 2011; 100: 2182-2193.
42. Arthur FKN, Woode E, Terlabi EO, Larbie C. Bilirubin lowering potential of *Annona muricata* (Linn.) in temporary jaundiced rats. *Am J Pharmacol Toxicol* 2012; 7: 33-40.
43. Li Y, Wang E, Patten CJ, Chen L, Yang CS. Effects of flavonoids on cytochrome P450-dependent acetaminophen metabolism in rats and human liver microsomes. *Drug Metab Dispos* 1994; 22: 566-571.
44. Myhrstad MC, Carlsen H, Nordström O, Blomhoff R, Moskaug JØ. Flavonoids increase the intracellular glutathione level by transactivation of the gamma-glutamylcysteine synthetase catalytical subunit promoter. *Free Radic Biol Med* 2002; 32: 386-393.
45. Johnson WM, Wilson-delfosse AL, Mieyal JJ. Dysregulation of glutathione homeostasis in neurodegenerative diseases. *Nutrients* 2012; 4: 1399-1440.
46. Penninckx MJ. An overview on glutathione in *Saccharomyces* versus non-conventional yeasts. *FEMS Yeast Res* 2002; 2: 295-305.