

Original Article

## Modulatory effect of quercetin on aspirin-induced hepatotoxicity in Wistar rats

Modupe Adebajji Akingbade<sup>1</sup>, Olamide Adegoke-Kehinde<sup>1</sup>, Charles Oluwafemi Faeji<sup>2</sup>, Ayodeji Fasoro<sup>3</sup>

<sup>1</sup>Department of Anatomy, Ekiti State University, Ekiti State, Nigeria, <sup>2</sup>Department of Science, College of West Anglia, Kings Lynn, United Kingdom,

<sup>3</sup>Department of Public Health, University of Otago, Wellington, New Zealand.

### \*Corresponding author:

Charles Oluwafemi Faeji,  
Department of Science, College  
of West Anglia, Kings Lynn,  
United Kingdom.

charles.faeji@cwa.ac.uk

Received: 21 February 2024  
Accepted: 27 September 2024  
Epub Ahead of Print: 14 January 2025  
Published:

DOI  
10.25259/IJPP\_73\_2024

Quick Response Code:



### ABSTRACT

**Objectives:** Aspirin, also known as acetylsalicylic acid, is a non-steroidal anti-inflammatory drug medication. Aspirin has been shown to have a wide range of pharmacological effects, such as antipyretic, antiplatelet and analgesic effects. Although there is little known about how aspirin causes hepatotoxicity at the cellular level, this does happen and there is a need to look into some hepatoprotective remedies. The aim of this study was to assess how quercetin (QE) affects aspirin-induced hepatotoxicity in Wistar rats.

**Materials and Methods:** Thirty-five male adult Wistar rats divided into seven experimental groups were used in this study. These groups received different treatments: Some were given varying concentrations of QE (30 mg/kg and 60 mg/kg), while others received aspirin (50 mg/kg). In addition, there were control groups that did not receive either aspirin or QE, with normal saline and corn oil being administered instead. The administration of treatments lasted for 30 days, after which the experiment was concluded, and the rats' livers were removed for histological examination. Simultaneously, blood serum samples were collected for the biochemical analysis of liver enzyme markers. The level of significance was set at 0.05, and the data collected was analysed using the Statistical Package for the Social Sciences version 29.

**Results:** It was found that aspirin increased the level of liver enzyme markers in the serum after 30 days of administration resulting from damage to the liver cells, this effect was most significant at an aspirin concentration of 50 mg/kg and QE at a concentration of 60 mg/kg was most effective in exhibiting hepatoprotective potentials.

**Conclusion:** The results suggest that aspirin 50 mg/kg could be hepatotoxic due to the lessening of antioxidant effects, and QE has a modulating effect on aspirin-induced toxicity.

**Keywords:** Quercetin, Hepatotoxicity, Aspirin, Wistar rats

### INTRODUCTION

Hepatotoxicity is the term used to describe damage to the liver or impairment of liver function resulting from exposure to xenobiotics, which include medications, food additives, alcohol, chlorinated solvents, peroxidised fatty acids and even certain medicinal plants.<sup>[1]</sup> Medication-induced liver damage, or hepatotoxicity, has been linked to several liver ailments.<sup>[2]</sup> There are about 900 known substances that can harm the liver, including poisons, medications and herbs. Twenty to forty per cent of cases of different types of liver failure are related to drugs.<sup>[1,3]</sup>

Employing non-steroidal anti-inflammatory drugs such as aspirin in the management of inflammatory conditions or as a preventive measure against various diseases stands out as one of

This is an open-access article distributed under the terms of the Creative Commons Attribution-Non Commercial-Share Alike 4.0 License, which allows others to remix, transform, and build upon the work non-commercially, as long as the author is credited and the new creations are licensed under the identical terms.

©2025 Published by Scientific Scholar on behalf of Indian Journal of Physiology and Pharmacology

the most efficacious approaches.<sup>[4]</sup> About 50 million individuals routinely use low-dose aspirin to avoid cardiovascular problems, according to recent research.<sup>[5]</sup> Analgesic, antipyretic and anti-inflammatory properties are originally associated with aspirin, and low-dose aspirin is also often used to prevent cardiovascular disease.<sup>[4]</sup>

Aspirin works by inhibiting cyclooxygenase, the rate-limiting enzyme that prevents arachidonic acid from being converted to prostaglandin and thromboxanes.<sup>[4]</sup> To prevent abuse, medical professionals emphasise the dose-related nature of aspirin-induced hepatotoxicity and link it to its metabolite, salicylic acid. However, since many people tend to ignore this warning, there is a possibility of abuse.<sup>[6]</sup>

One important flavonoid that is widely present in fruits, leafy and pod vegetables, and red wine is quercetin (QE), which is also an essential part of the human diet.<sup>[7]</sup> In addition to its direct hydrogen atom donation and Michael acceptor function in quenching of reactive oxygen species (ROS), QE also directly interacts with intracellular signalling cascades linked to antioxidant function, activating the endogenous antioxidative defence system.<sup>[7,8]</sup>

Research suggests that QE may have hepatoprotective effects by promoting HO-1 expression, and according to Zargar and Wani,<sup>[9]</sup> QE has antioxidant qualities that help prevent some illnesses, such as cirrhosis, brain damage, liver fibrosis, cardiovascular problems, atherosclerosis and biliary obstruction.<sup>[10]</sup> QE has garnered attention lately due to its exceptional array of health advantages, positioning it as a crucial ingredient in the creation of innovative and effective multifunctional foods and medications.<sup>[11,11]</sup> Numerous biological benefits of QE have been shown, including hepatoprotective, renoprotective, antioxidative, anti-inflammatory, antiapoptotic, neuroprotective and cardioprotective properties.<sup>[7,9]</sup> In light of this, the purpose of our research is to ascertain if QE has a modulatory or restorative impact on aspirin-induced hepatotoxicity in male Wistar rats.

## MATERIALS AND METHODS

### Study design

The study was conducted on 35 adult male rats (weighing 200–230 g) over 30 days. The animals were housed in stainless steel wire cages suspended from the ceiling and kept in a temperature-controlled environment (23–25°C) and humidity (40–60%). The animals were randomly divided into seven (7) groups of 5 rats [Table 1]. Each group of rats was allowed adequate access to water (*ad libitum*) and standard rat chow for 4 weeks with 2 weeks of acclimatisation. Aspirin (acetylsalicylic acid) and QE (flavonoid) tablets/drugs were obtained from a registered pharmacy. Aspirin was dissolved in normal saline, while QE was dissolved in corn oil. QE is a flavonoid compound

that is poorly soluble in water. Dissolving it in an oil-based solvent, such as corn oil, improves its solubility, making it easier to administer and ensuring better absorption in the body, while aspirin is soluble in normal saline, which is also a solvent known for its biocompatibility with the body. Both solutions were stored at +4°C to prevent repeated preparation. The dose was administered orogastrically to each rat based on body weight for 30 days. Ethical approval for this experiment was obtained from the Ethics and Research Committee of the Department of Anatomy, College of Medicine, Ekiti State University, Ado-Ekiti (File no: ERCANA/2023/12/001) before the study commenced. The National Institute of Health Guidelines for the Care and Use of Laboratory Animals were followed in all procedures and techniques in this investigation.<sup>[12]</sup>

### Sample collection and preparation

Rats were weighed using a calibrated Leica model weighing scale after the period of acclimatisation (2 weeks), which was before the treatment period and then at intervals of 10 days post-treatment. At the end of the feeding period, the animals were allowed to fast overnight, anaesthetised with chloroform and 5 ml of whole blood sample was obtained from the Wistar rats through cardiac puncture positioned in dorsal recumbency and dispensed into plain tubes. Serum was obtained from whole blood by centrifuging at 2000 rpm for 10 min using a bucket centrifuge. Serum was collected separately for each sample with the help of a micropipette and stored at –20°C until analysis for liver biochemical markers. The rat was dissected, and the liver was harvested, this was fixed immediately in 5% formaldehyde.<sup>[1]</sup>

### Biochemical analysis

Aspartate aminotransferase (AST), alanine aminotransferase (ALT) and alkaline phosphatase (ALP) were estimated using RANDOX Kit (RANDOX online store SKU: AS3804, SKU: AL1205, SKU: AP8002) according to the method used in previous studies.<sup>[1,13]</sup>

### Tissue processing

Histological processes were carried out using a tissue processor following the standard histological processing schedule. A rotary microtome was utilised to cut the tissues, which were then stained with haematoxylin and eosin (H&E). The liver was cleaned after being fixed in a formalin solution and diced. Subsequently, the tissue underwent paraffin sectioning, and a tissue block was created. The block was then cut into 5 µm thickness using a rotary microtome and stained with H&E. Finally; the slides were observed using a light microscope.<sup>[1]</sup>

## Data analysis

The collected results were statistically assessed using the Statistical Package for the Social Sciences version 29. Data were subjected to a one-way analysis of variance, and differences were considered statistically significant at  $P < 0.05$ , and a *post hoc* Tukey test was performed to determine the difference amongst the seven groups.

## RESULTS

Table 2 shows that the administration of 30 mg/kg QE and corn oil to Wistar rats did not result in a statistically significant elevation in ALT, ALP, and AST activities compared to the control group. However, the administration of 50 mg/kg of aspirin orally significantly elevated ALT levels in the serum compared with the control group.

## DISCUSSION

The findings of our research demonstrated that severe histological changes in hepatic tissue corroborated hepatic injury [Figure 1] and deviations from normal values of hepatic enzymes in serum [Table 2] caused by oral administration or exposure to aspirin, particularly at a dose of 50 mg/kg. Due to the fact that xenobiotic metabolism is one of the liver's primary functions, it is exceptionally susceptible to injury

from toxic xenobiotics.<sup>[14]</sup> Serum concentrations of hepatic enzymes serve as biomarkers to evaluate the health and function of the liver. These enzymes are alternatively referred to as liver function markers.

The utilisation of liver function markers is critical for the detection and surveillance of liver diseases and injury. In general, increased concentrations of hepatic enzymes in the serum are indicative of severe injury to the cell membranes and structural integrity of the liver.<sup>[1]</sup> Assays for serum concentrations of AST, ALT and ALP were performed to diagnose cholestasis and/or liver damage.

Because ALT is predominately detected in the liver, it serves as a more precise indicator for identifying liver abnormalities. ALP and AST are additional enzymes utilised in the evaluation of hepatotoxicity. Liver impairment is accompanied by elevated concentrations of AST in additional organs, including the brain, heart, musculature and kidneys.<sup>[15]</sup> In addition, elevated serum ALP levels are considered an indicator of hepatotoxicity.<sup>[1]</sup>

Hepatic enzymes are secreted into the circulation subsequent to cellular membrane impairment and demise of liver cells. Consequently, after 30 days of oral administration of 50 mg/kg aspirin, a significant increase in its concentration within the hepatic tissue is observed, resulting in hepatotoxicity and cell death. This discovery is consistent with prior research that has demonstrated hepatotoxicity caused by aspirin during both subchronic and chronic exposure.<sup>[16]</sup>

The findings of our study demonstrated that the administration of 50 mg/kg of aspirin orally significantly elevated ALT levels in the serum [Table 2] in comparison with the control group ( $P < 0.05$ ). The results presented here are consistent with prior research conducted on hepatic injury induced by aspirin.<sup>[17,18]</sup> Proposed that oxidative stress may be one of the mechanisms by which aspirin induces liver injury.<sup>[19]</sup> Consistent with prior research, which has

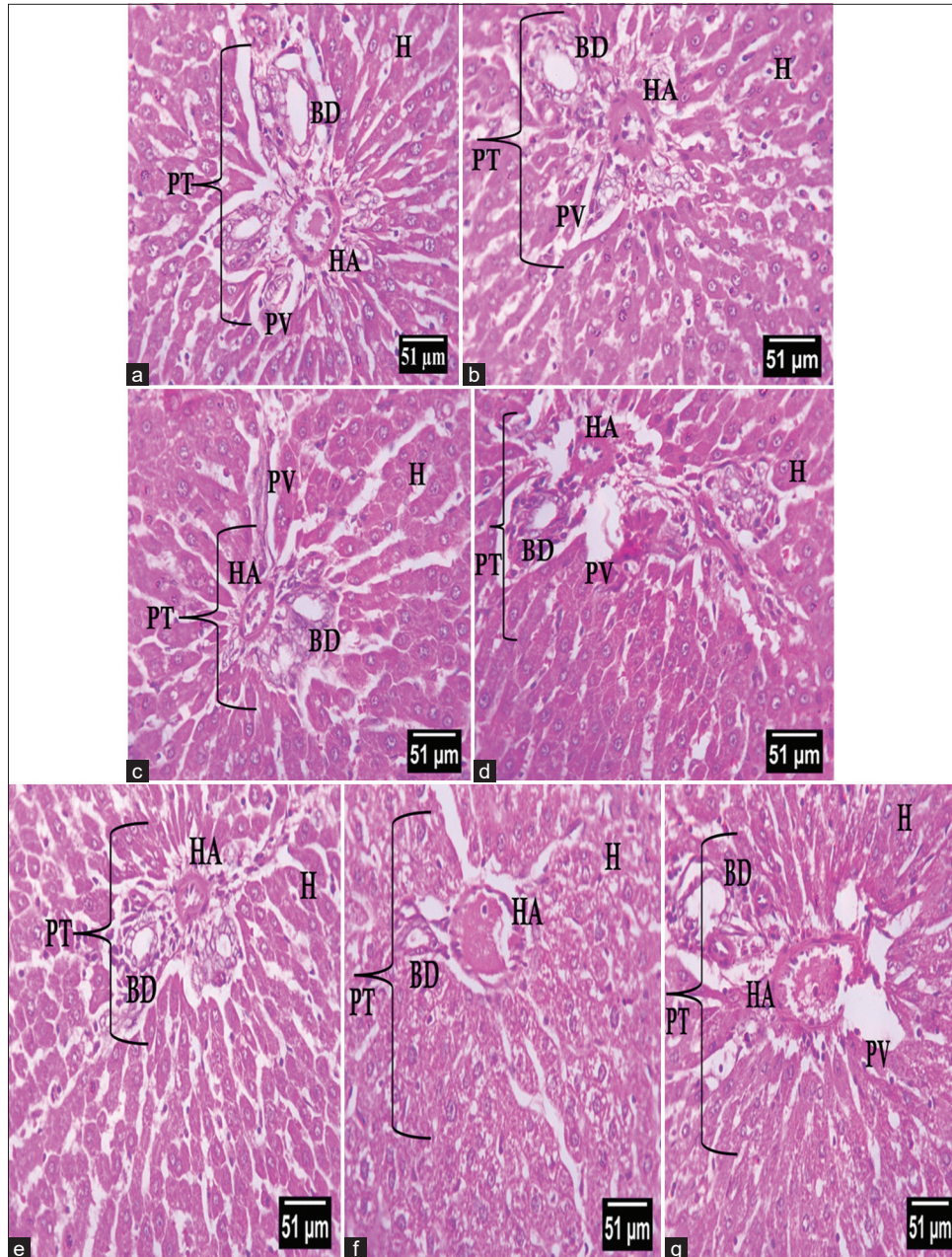
**Table 1:** Experimental design groups.

S. No.	Treatment Groups	Dosage
1.	Normal saline control	9.30 mL/kg body weight
2	Corn oil control	9.30 mL/kg body weight
3	Quercetin only	30 mg/kg body weight
4	Quercetin only	60 mg/kg body weight
5	Aspirin only	50 mg/kg body weight
6	Quercetin+Aspirin	30 mg/kg+50 mg/kg body weight
7	Quercetin+Aspirin	60 mg/kg+50 mg/kg body weight

**Table 2:** Effect of aspirin and quercetin on liver marker enzyme activities on male albino Wistar rats.

Experimental groups	Parameters (U/L)		
	AST	ALT	ALP
A: Normal saline control	6.13±0.74	9.75±1.48	2.25±0.56
B: Corn oil control	6.50±1.12	9.88±1.75	2.25±1.15
C: Quercetin control 30 mg/kg	6.50±1.12	9.88±2.41	2.38±0.96
D: Quercetin control 60 mg/kg	4.75±1.47 <sup>c</sup>	7.75±1.48 <sup>c</sup>	2.25±1.09
E: Aspirin control 50 mg/kg	7.00±1.58	13.37±2.72 <sup>a</sup>	4.00±0.79 <sup>bc</sup>
F: Quercetin 30 mg/kg+aspirin 50 mg/kg	5.75±1.09	10.00±1.58 <sup>d</sup>	3.38±0.96
G: Quercetin 60 mg/kg+aspirin 50 mg/kg	5.25±0.83	9.00±1.58 <sup>d</sup>	3.00±0.79

Values are expressed as mean±standard deviation, <sup>a</sup>Significant difference at  $P < 0.05$  when corn oil and quercetin group (30 mg/kg, 60 mg/kg) are compared with aspirin-induced Group, <sup>b</sup>Significant difference at  $P < 0.05$  when aspirin-induced (50 mg/kg) group is compared with control group, <sup>c</sup>Significant difference at  $P < 0.05$  when quercetin group (60 mg/kg) is compared with the control group, <sup>d</sup>Significant difference at  $P < 0.05$  when quercetin 30 mg/kg or 60 mg/kg+aspirin 50 mg/kg is compared with aspirin-induced group. AST: Aspartate aminotransferase, ALT: Alanine aminotransferase, ALP: Alkaline phosphatase



**Figure 1:** (a) The control group exhibits normal architecture of liver tissue. It shows normal and distinct liver cell (hepatocyte). (b) Showing histological section of the hepatocyte of rat fed with observed in rat fed with corn oil. (c) Showing histological section of the hepatocyte of rat fed with quercetin 30 mg/kg when compared with the control. (d) Showing histological section of the hepatocyte of rat fed with liver pre-treated with quercetin 60 mg/kg. All liver sections were stained with haematoxylin and eosin. (e) Showing mild vacuolar degeneration and shrunken portal area of the rat liver tissue pre-treated with aspirin 50 mg/kg (Group E). (f) Showing mild degeneration of the Wistar rat hepatocyte after co-treatment of aspirin 50 mg/kg + quercetin 30 mg/kg when compared with control. (g) Showing hepatocyte rat after co-treatment of aspirin 50 mg/kg + quercetin 60 mg/kg when compared with control. All liver section was stained with the haematoxylin and eosin (H: Hepatocyte, PV: Portal vein; BD: Bile duct, HA: Hepatic artery, PT: Portal triad).

demonstrated oxidative stress in hepatic tissue as a result of excessive ROS production and disruption of the antioxidant

defence system subsequent to exposure, these results align with this notion.

In addition, Table 2 demonstrated that the administration of 30 mg/kg QE and corn oil to Wistar rats did not result in a statistically significant elevation in ALT, ALP, and AST activities compared to the control group. Compared to the control group, Wistar rats that were given 60 mg/kg of QE exhibited non-significant increases in ALT, AST, and ALP levels. Consistent with previous research by Rahmani *et al.*,<sup>[1]</sup> these results suggest that QE and corn oil do not cause liver damage.

We also examined the potential protective effect of QE against aspirin-induced hepatotoxicity in the present study. Co-administering 60 mg/kg of QE and 50 mg/kg of aspirin prevented aspirin-induced liver toxicity, and ALT, ALP and AST activities did not increase significantly in comparison to the control group, as indicated by our findings. This indicates that, according to histological evaluations, it was effective in preventing liver injury in comparison to the control group. These results were consistent with those of Rahmani *et al.*<sup>[1]</sup> and Ghazanfari *et al.*<sup>[20]</sup>

The pathogenesis of aspirin toxicity is significantly influenced by inflammation, which is partially facilitated by endogenous and migrating leukocytes.<sup>[16]</sup> Inhibiting ROS by scavenging them and reducing neutrophil accumulation in the liver is a potential mechanism by which QE achieves the asserted result and histological effect. Prior research has demonstrated that the administration of antioxidant agents mitigated hepatocyte damage and averted leukocyte accumulation in liver tissue, which is consistent with the current findings.<sup>[20,21]</sup>

Hepatic enzyme levels were nearly normal in animals that were administered aspirin in conjunction with QE. Hence, this indicates that the hepatoprotective properties of QE against the toxicity induced by aspirin are primarily facilitated by its antioxidant attributes.<sup>[1]</sup> QE possesses hepatoprotective and antioxidant properties and is classified as a flavonoid. Numerous fruits and vegetables contain flavonoids, which are a genus of flavonols with numerous pharmacological and therapeutic properties, including antibacterial, antinociceptive (pain relieving), anxiolytic, antidepressant, anti-allergic, anti-proliferative and antioxidant effects. In addition, it effectively combats hypertension, diabetes, diabetic neuropathy, platelet aggregation and thrombus formation.<sup>[22]</sup>

The histology of liver sections from rats in both the control and QE 30 mg/kg groups appeared normal, as shown in Figure 1. The arrangement of hepatocytes, blood vessels and sinusoids appeared to be in the expected configuration. Biliary ducts were also observed to be in good health, with no indications of cholestasis. No pathological alterations were observed in the liver tissue. Compared to the control group, the 60 mg/kg group treated with corn oil and QE had a radial distribution of hepatocytes around central veins [Figure 1]. This finding is consistent with the research conducted by Rafeeq *et al.*<sup>[19]</sup> and Rahmani *et al.*<sup>[1]</sup>

In comparison to the control group, the aspirin + QE 60 mg/kg group [Figure 1] exhibited only a minor perturbation of hepatocytes. This suggests that high concentrations of QE may protect against complete disruption of hepatocytes. This aligns with the findings of Ghazanfari *et al.*<sup>[20]</sup> By scavenging oxygen radicals, protecting against lipid peroxidation, inhibiting calcium channel activity and chelating metal ions, QE prevents oxidant damage and cell mortality.<sup>[23]</sup> As a result, it is hypothesised that QE protected the hepatocytes of animals that were co-administered with aspirin and QE from oxidative damage and mortality by scavenging excessively produced ROS caused by aspirin oral exposure.

Mild vacuolar degeneration, massive hepatocyte damage, necrosis and inflammatory cell infiltration were observed in the histological section of the rats in the aspirin 50 mg/kg group and the aspirin 50 mg/kg + QE 30 mg/kg group [Figure 1]. In addition, the tissue section revealed congestion and disruption in the portal vein region. This finding aligns with prior investigations concerning liver impairment induced by aspirin.<sup>[19]</sup> This further suggests that a minimal quantity of QE is insufficiently potent to mitigate or restrict the impact of liver toxicity induced by aspirin. This is consistent with the findings of Rahmani *et al.*,<sup>[1]</sup> who stated that a high dose of QE is required to ameliorate liver damage efficiently. This may be attributed to the diminished concentration of antioxidants and the high abundance of free radicals produced by apoptosis and inflammation, given that hepatotoxicity induced by aspirin is a progressive effect that can take days or weeks to manifest.

## CONCLUSION

Prolonged administration of aspirin at a dosage of 50 mg/kg may result in hepatic complications and alterations in the histological structure of the liver; therefore, this dosage should be reserved for short-term use only. QE demonstrated effective modulatory and hepatoprotective effects against aspirin-induced hepatotoxicity. QE may be regarded as a prospective nutraceutical product that could serve to mitigate hepatotoxicity in individuals who are acutely exposed to excessive dosages or abuse of aspirin.

## Authors' contributions

Modupe Adebajji Akingbade and Olamide Adegoke-Kehinde conceived and designed the study. All authors contributed to the conduct of the experiments and data collection. Charles Oluwafemi Faeji and Ayo Fasoro analysed the data and wrote the first draft of the manuscript. All authors contributed to and approved the final draft.

## Ethical approval

The research/study was approved by the Institutional Review Board at the College of Medicine, Ekiti State University, number ERCANA/2023/12/001, dated April 05, 2023.

### Declaration of patient consent

Patient's consent is not required as there are no patients in this study.

### Financial support and sponsorship

Nil.

### Conflicts of interest

There are no conflicts of interest.

### Use of artificial intelligence (AI)-assisted technology for manuscript preparation

The authors confirm that there was no use of artificial intelligence (AI)-assisted technology for assisting in the writing or editing of the manuscript and no images were manipulated using AI.

### REFERENCES

- Rahmani F, Najafzadeh P, Mousavi Z, Rastegar T, Barzegar E. The protective effect of quercetin against hepatotoxicity induced by doxorubicin in male rats. *Iranian J Pharmacol Ther* 2018;16:1-8.
- Ekozin A, Otuechere CA, Adewuyi A. Apocynin loaded silver nanoparticles displays potent *in vitro* biological activities and mitigates pyrogallol-induced hepatotoxicity. *Chem Biol Interact* 2022;365:110069.
- Jaeschke H, Gores GJ, Cederbaum AI, Hinson JA, Pessayre D, Lemasters JJ. Mechanisms of hepatotoxicity. *Toxicol Sci* 2002;65:166-76.
- Doi H, Horie T. Salicylic acid-induced hepatotoxicity triggered by oxidative stress. *Chem Biol Interact* 2010;183:363-8.
- Baraiya PD, Patel JM, Vihol PD, Raval JK, Parmar HC, Patel SA, *et al.* Effects of quercetin on aspirin-induced haemato-biochemical alterations in wistar rats. *Indian J Vet Sci Biotechnol* 2023;19:42-5.
- Shehu AI, Ma X, Venkataramanan R. Mechanisms of drug-induced hepatotoxicity. *Clin Liver Dis* 2017;21:35-54.
- Salehi B, Machin L, Monzote L, Sharifi-Rad J, Ezzat SM, Salem MA, *et al.* Therapeutic potential of Quercetin: New insights and perspectives for human health. *ACS Omega* 2020;5:11849-72.
- Dorrigiv M, Zareiyan A, Hosseinzadeh H. Onion (*Allium cepa*) and its main constituents as antidotes or protective agents against natural or chemical toxicities: A comprehensive review. *Iran J Pharm Res* 2021;20:3-26.
- Zargar S, Wani TA. Protective role of quercetin in carbon tetrachloride induced toxicity in rat brain: Biochemical, spectrophotometric assays and computational approach. *Molecules* 2021;26:7526.
- Fuentes J, de Camargo AC, Atala E, Gotteland M, Olea-Azar C, Speisky H. Quercetin oxidation metabolite present in onion peel protects Caco-2 cells against the oxidative stress, NF-kB activation, and loss of epithelial barrier function induced by NSAIDs. *J Agric Food Chem* 2021;69:2157-67.
- Madrigal-Santillán E, Madrigal-Bujaidar E, Álvarez-González I, Sumaya-Martínez MT, Gutiérrez-Salinas J, Bautista M, *et al.* Review of natural products with hepatoprotective effects. *World J Gastroenterol* 2014;20:14787-804.
- National Research Council. Guide for the care and use of laboratory animals. 8<sup>th</sup> ed. Washington, DC: The National Academies Press; 2011.
- Aprioku JS, Amamina AM, Nnabuenyi PA. Mancozeb-induced hepatotoxicity: Protective role of curcumin in rat animal model. *Toxicol Res (Camb)* 2023;12:107-16.
- Tittarelli R, Pellegrini M, Scarpellini MG, Marinelli E, Bruti V, di Luca NM, *et al.* Hepatotoxicity of paracetamol and related fatalities. *Eur Rev Med Pharmacol Sci* 2017;21:95-101.
- Aboobecker S, Bajpai A, Srivastava R, Tewari R, Hooda M. To study analgesic, hypoglycemic and hepatoprotective activity of *Moringa oleifera* leaf extract in Albino wistar rats. *J Drug Deliv Ther* 2019;9:730-6.
- Xu Y, Mu W, Li J, Ba Q, Wang H. Chronic cadmium exposure at environmental-relevant level accelerates the development of hepatotoxicity to hepatocarcinogenesis. *Sci Total Environ* 2021;783:146958.
- Kannan N, Sakthivel KM, Guruvayoorappan C. Protective effect of *Acacia nilotica* (L.) against acetaminophen-induced hepatocellular damage in wistar rats. *Adv Pharmacol Sci* 2013;2013:987692.
- Adewoga T, Sebiomo A. The effect of honey and *Aloe vera* extract on aspirin induced liver damage in rats. *Afr J Cell Pathol* 2014;2:53-8.
- Rafeeq A, Najam R, Hussain S. Aspirin associated liver toxicity- the optimal dose of aspirin in liver insufficiency. *Int J Sci Res Knowl* 2016;4:28-32.
- Ghazanfari A, Soodi M, Omidi A. Quercetin ameliorates acetamidiprid-induced hepatotoxicity and oxidative stress. *Physiol Pharmacol* 2021;25:154-61.
- Veronese P, Dodi I, Esposito S, Indolfi G. Prevention of vertical transmission of hepatitis B virus infection. *World J Gastroenterol* 2021;27:4182.
- Ali FT, Hassan NS, Abdrabou RR. Hepatoprotective and antiproliferative activity of moringinine, chlorogenic acid and quercetin. *Int J Res Med Sci* 2016;4:1147-53.
- Choi KC, Chung WT, Kwon JK, Yu JY, Jang YS, Park SM, *et al.* Inhibitory effects of quercetin on aflatoxin B1-induced hepatic damage in mice. *Food Chem Toxicol* 2010;48:2747-53.

**How to cite this article:** Akingbade MA, Adegoke-Kehinde O, Faeji CO, Fasoro A. Modulatory effect of quercetin on aspirin-induced hepatotoxicity in Wistar rats. *Indian J Physiol Pharmacol*. doi: 10.25259/IJPP\_73\_2024