

Original Article

Acute oral toxicity evaluation of *p*-propoxybenzoic acid in Sprague-Dawley rats according to OECD guideline 425 – Up-and-down method

Keval Raval^{1,2}, Pravin Tirgar²

¹Department of Pharmacology, Ramanbhai Patel College of Pharmacy, CHARUSAT University, Anand, ²Department of Pharmacology, School of Pharmacy, RK University, Tramba, Rajkot, Gujarat, India.

*Corresponding author:

Keval Raval,
Department of Pharmacology,
Ramanbhai Patel College
of Pharmacy, CHARUSAT
University, Anand, Gujarat,
India.

kevalraval.ph@charusat.ac.in

Received: 20 January 2024
Accepted: 12 August 2024
Epub Ahead of Print: 29 November 2024
Published:

DOI
10.25259/IJPP_21_2024

Quick Response Code:



ABSTRACT

Objectives: The purpose of this study was to assess the acute oral toxicity of *p*-propoxybenzoic acid (*p*-PBA) following the Organisation for Economic Co-operation and Development Guideline 425.

Materials and Methods: Then animals were equally divided into two groups: *p*-PBA and normal control (NC). The standardised up-and-down procedure involved a limit test, starting with a 2000 mg/kg dose of *p*-PBA in one animal of the *p*-PBA group. On confirming the absence of toxicity in one animal, the remaining four animals of *p*-PBA and five animals of NC group were treated with the same dose of *p*-PBA and vehicle (1 mL, 0.1% carboxymethyl cellulose), respectively. Monitoring extended over a 14-day period, encompassing observations of body weight, behavioural patterns, blood serum parameters and histopathological examinations.

Results: The study revealed no significant difference in the body weight of the *p*-PBA and NC groups over the 14-day observation period. Behavioural patterns, including respiration, sleep tendencies and itching, showed transient alterations in the *p*-PBA group, returning to baseline within the study period. Blood parameters, serum renal and lipid profile displayed no statistically significant differences between the groups. Histopathological analysis demonstrated no hypertrophy or abnormalities in the heart, kidney and liver. Minor muscular damage was observed in the heart and a loose network of neurons in the cerebellum.

Conclusion: The absence of significant adverse effects on body weight, behavioural patterns and vital organs suggests a favourable safety profile. Minor histopathological findings indicate a nuanced impact on cardiac and neurological tissues, warranting further investigation. The study revealed the acute oral toxicity of *p*-PBA supporting its potential therapeutic applications.

Keywords: *p*-propoxybenzoic acid, Acute toxicity study, Sprague-Dawley rats, Organisation for Economic Co-operation and Development 425 Guideline, Safety profile

INTRODUCTION

p-propoxybenzoic acid is (*p*-PBA) a natural chemical constituent present in various plant species, including *Trienthera porulacastrum*,^[1] *Trienthera decandra*,^[1] *Daphe oleoides*^[2] and *Euonymus alatus*.^[3] A study has highlighted the potential antimicrobial and aphrodisiac activity of *p*-PBA extracted from the stem bark of *Acacia auriculiformis*.^[4] In our previous work, we assessed the preliminary anti-diabetic potential of *p*-PBA through the modulation of α -amylase and protein tyrosine phosphatase 1B enzyme.^[5] In addition, a study also

demonstrated the α -glucosidase inhibitory activity of *p*-PBA with a submaximal inhibitory concentration of $14.8 \pm 0.9 \mu\text{M}$.^[6] Furthermore, we assessed the protective effect of *p*-PBA in diabetic conditions induced in rats through streptozotocin and nicotinamide.^[7] Our unpublished data also exhibit significant results on the chemopreventive effect of *p*-PBA through *in silico* and *in vitro* studies. While several preliminary studies support the therapeutic potential of *p*-PBA, there remains a scarcity of studies including pre-clinical animal trials. To address this gap, we conducted an acute oral toxicity study to provide insights into the safety and toxicity profile of *p*-PBA.

An acute oral toxicity study for *p*-PBA was conducted following the Organisation for Economic Co-operation and Development (OECD) Guideline 425 – up-and-down method.^[8] In this study, female Sprague-Dawley (SD) rats were utilised following the recommendation of OECD Guideline 425.^[8] The standardised up-and-down method for the toxicity study involves the estimation of toxicity through a limit test, starting with a single dose in one animal and subsequent adjustment of the dose based on the animal response.^[8] Assessment through the acute oral toxicity study may enable the conduction of *p*-PBA single-dose studies in animals.

We postulated that examining the toxicity and safety profile of *p*-PBA may allow the further exploration of its therapeutic potential through pre-clinical studies. Here, we present the possible toxicity effects of *p*-PBA in female SD rats on a single dose. The objectives of the study were to analyse the possible changes in body weight, behavioural patterns, serum lipid parameters and serum kidney parameters. In addition, we explored the possible toxic effects of *p*-PBA on vital organs, including the liver, kidney, heart and brain, through gross necropsy and histopathological analysis.

MATERIALS AND METHODS

Materials

The interventional compound *p*-PBA [CAS: 5438-19-7] was sourced from Fisher Scientific. Additional reagents, including carboxymethyl cellulose (CMC) [CAS: 9000-11-7], ketamine [CAS: 6740-88-1], isoflurane [CAS: 26675-46-7] and hematoxylin [CAS: 517-28-2], were purchased from Thermo Fisher Scientific. Test kits for the estimation of serum renal parameters and serum lipid parameters were procured from Thermo Fisher Scientific.

Animals

The study employed ten nulliparous, non-pregnant female SD rats with an average weight of 240.2 ± 3.5 grams procured from the School of Pharmacy, RK University. This research

was undertaken in accordance with the Institute Animal Ethics Committee under the reference number RKCP/COI/Re/22/128. Before conducting the experiments, the animals underwent an acclimatisation period. The rats had unrestricted access to water and food in controlled environmental conditions at $23 \pm 3^\circ\text{C}$ temperature and 36–65% relative humidity.

Acute oral toxicity assay

The assay was conducted following the OECD Guideline 425: Up-and-down procedure.^[8] Rats were divided into two groups: *p*-PBA and normal control (NC), containing five animals in each group. A limit test was conducted in a single rat of the *p*-PBA group through an oral administration of 2000 mg/kg dose of *p*-PBA solution prepared in 1% CMC. The animals were subjected to a 12-h period of fasting before dosing while maintaining free access to water. The treated rat was continuously monitored during the initial 30 min post-dosing and for the subsequent 4 h. Food was provided 1–2 h after dosing. On confirming the survival of the initially treated rat, the same dose and conditions were applied to four additional rats of the *p*-PBA group. A parallel procedure was carried out for an NC group of five rats treated with 1% CMC solution in a volume equivalent to the treated group. Animals of both groups were subjected to close observation for any signs of toxicity within the first 6 h, with subsequent regular monitoring during the study duration of 14 days. The onset of toxic reactions, if any, was documented.

Body weight

The body weight of each animal was recorded 3 times within the study duration (Day 1, Day 7 and Day 14).

Changes in behavioural patterns

Changes in patterns of respiration, sleep tendencies, ocular movements, urination, faecal consistency, and itching, as well as changes in fur and skin condition, were recorded at different time intervals following treatment administration. Observations were made at 30 min, 4 h, 24 h, 48 h, 7 days and 14 days post-treatment. In addition, occurrences of convulsions, comatose states and mortality were monitored throughout the treatment duration.

Collection of blood sample

Blood samples from all animals were obtained through retro-orbital puncture for biochemical and haematological evaluations.^[9] Blood samples were collected in serum tubes and ethylenediaminetetraacetic acid tubes for biochemical analysis and haematological analysis, respectively.

Haematological analysis

Haematological analysis of blood was conducted following the standard protocol.^[10] Briefly, the anticoagulated blood samples were promptly subjected to haematological parameter assessments using an automated analyser. The parameters evaluated included haemoglobin concentration, total red blood cell count, platelet count, white blood cell count, haematocrit, eosinophils, neutrophils, lymphocytes, mean corpuscular volume, mean corpuscular haemoglobin concentration and mean corpuscular haemoglobin.

Biochemical analysis

Blood samples with partial clot formation were centrifuged at 3000×g for 10 min at a temperature of 4°C to obtain serum. The serum samples were preserved at -20°C and subsequently subjected to analysis within a 24-h timeframe. The levels of various serum renal parameters, encompassing serum creatinine, serum albumin and total protein, as well as serum lipid parameters, including serum cholesterol, serum triglycerides, serum high-density lipoprotein, serum low-density lipoprotein and serum very low-density lipoprotein, were quantified using commercially available test kits following standard procedures.^[11,12]

Gross findings and organ weights

After the blood collection, the rats were euthanised with ketamine^[13] and a macroscopic gross necropsy was conducted. This examination included a thorough assessment of the heart, liver and kidney for any observable abnormalities. Subsequently, the heart, liver and kidney were collected, and their respective weights were determined. The relative organ-to-body weight ratio was collected by dividing the organ weight by fasting body weight and expressed as a percentage (organ weight/body weight × 100%).^[14]

Histopathological analysis

The organs, including the liver, heart, kidney and cerebellum, were isolated from three animals from each group and subjected to 10% formalin solution for preservation.

Tissue processing

Tissues were first submerged in formalin solution and subjected to isopropyl alcohol. The tissues were saturated with paraffin wax and secured within paraffin blocks. These blocks were utilised for the preparation of tissue sections. Subsequently, the sections were affixed to glass slides, and a uniform mixture of egg albumin and glycerol was applied after a period of floating in a tissue flotation solution at 40°C. The sections were further processed by melting them in an incubator set at 60°C for 5 min.

Tissue staining

The wax in the section was eliminated with xylene. Following deparaffinisation, the section was subjected to a washing step and staining with haematoxylin. Post-hematoxylin staining, the slides were subjected to a rinsing procedure to eliminate any excessive stain. Subsequently, counter-staining was done using eosin solution, and stained sections were subjected to incubation at 60°C. The resulting sections were observed at a ×40 magnification using an Olympus microscope.

Statistical analysis

Data are presented as mean ± standard error of the mean. Results were analysed utilising GraphPad Prism 9.5.1. A statistical analysis was conducted using a two-way analysis of variance followed by Tukey's *post hoc* method. $P < 0.05$ was considered as statistically significant.

RESULTS

Changes in body weight

Body weight comparison between the *p*-PBA group and NC group is given in Table 1. No statistically significant differences were observed in the body weight of the NC group and the *p*-PBA group throughout the study duration of 14 days.

Changes in behavioural patterns

Observation of changes in the behavioural patterns are recorded and presented in Table 2. No variations in the behavioural patterns were seen in the animals of the NC group. Respiration of the animals increased after 30 min of the *p*-PBA administration. Respiration of the animals treated with *p*-PBA returned to normal range within 4 h. Animals treated with *p*-PBA showed increased sleeping tendency between 4 h and 24 h after the drug administration. Animals administered with *p*-PBA demonstrated the presence of itching in the first 24 h of drug administration. Animals of both groups were shown a normal tendency of the behavioural patterns related to eyes, urination, face consistency, fur and skin. Incidence of critical abnormalities,

Table 1: Effect of *p*-PBA (2000 mg/kg) on the body weight.

Observation day	Body weight (g)	
	NC (0.1% CMC)	<i>p</i> -PBA (2000 mg/kg)
Day 1	240.83±7.28	242.00±4.8
Day 7	252.70±6.92	252.20±5.4
Day 14	264.31±9.24	264.37±9.4

CMC: Carboxymethyl cellulose, *p*-PBA: *p*-propoxybenzoic acid, NC: Normal control

Table 2: Changes in the behavioural patterns in rats over the treatment period.

Parameters	Observations over the treatment period											
	30 min		4 h		24 h		48 h		7 h		14 days	
	NC	<i>p</i> -PBA	NC	<i>p</i> -PBA	NC	<i>p</i> -PBA	NC	<i>p</i> -PBA	NC	<i>p</i> -PBA	NC	<i>p</i> -PBA
Fur and skin	S	S	S	S	S	S	S	S	S	S	S	S
Respiration	S	I	S	S	S	S	S	S	S	S	S	S
Sleeping tendency	S	S	S	I	S	I	S	S	S	S	S	S
Eyes	S	S	S	S	S	S	S	S	S	S	S	S
Urination	S	S	S	S	S	S	S	S	S	S	S	S
Faeces consistency	S	S	S	S	S	S	S	S	S	S	S	S
Itching	A	P	A	P	A	P	A	A	A	A	A	A
Convulsions	A	A	A	A	A	A	A	A	A	A	A	A
Coma	A	A	A	A	A	A	A	A	A	A	A	A
Mortality	A	A	A	A	A	A	A	A	A	A	A	A

A: Absent, I: Increased, NC: Normal Control, P: present, *p*-PBA: *p*-propoxybenzoic acid, S: Stable

including convulsions, coma or mortality, was not found in animals of both groups.

Changes in serum renal parameter levels

A comparison of serum creatinine, serum albumin and total protein between the *p*-PBA group and the NC group is given in Table 3. Administration of *p*-PBA exhibited no significant differences in the renal in comparison with the NC group.

Changes in serum lipid parameter levels

Levels of different lipid parameters are presented in Table 4. The assessment of lipid profile in rats treated with *p*-PBA revealed no statistically significant differences in levels of lipid parameters when compared with the NC group.

Changes in haematological profile

Various haematological parameters were derived and compared for *p*-PBA and NC, which are presented in Table 5. The complete blood count profile of rats treated with *p*-PBA exhibited no statistically significant differences in various parameters compared to the NC group.

Changes in organ-body weight ratio

A comparison of the organ-body weight ratio is provided in Table 6. The organ-body weight ratio of the heart, liver and right kidney in rats treated with *p*-PBA exhibited no statistically significant difference compared to the animals in the NC group.

Histopathological analysis

Figures 1a and b indicate the comparison of histopathological changes in the liver between the *p*-PBA group and the NC

Table 3: Effect of *p*-propoxybenzoic acid on renal parameter levels in rats over the treatment period.

Parameters (Unit)	Treatment groups	
	NC (0.1% CMC)	<i>p</i> -PBA (2000 mg/kg)
Serum creatinine (mg/dL)	0.41±0.02	0.37±0.05
Serum albumin (mg/dL)	4.17±0.04	3.99±0.07
Total protein (mg/dL)	10.45±0.44	10.45±0.37

CMC: Carboxymethyl cellulose, *p*-PBA: *p*-propoxybenzoic acid, NC: Normal control

group. No histopathological abnormalities were found in the animals of the NC group. A small incidence of patchy necrosis was observed in the animals of the *p*-PBA group.

The presence of muscular damage in cardiac tissue was observed in the cerebellum of the animals of the *p*-PBA group. No changes were observed in the animals of the NC group. Figures 2a and b indicate heart histopathology of the NC group and the *p*-PBA (2000 mg/kg) group, respectively.

Figures 3a and b illustrate the histopathology of the kidney in the NC group and the *p*-PBA group, respectively. No notable changes were observed in the comparison of kidney histopathology between the NC group and the *p*-PBA (2000 mg/kg) group.

Histopathology of the cerebellum is given in Figures 4a and b for the NC group and *p*-PBA group, respectively. Cerebellum histopathology of animals treated with *p*-PBA showed a loose network of neurons in comparison with the NC group. No serious complications were observed in either group.

DISCUSSION

In spite of the numerous therapeutic potentials attributed to *p*-PBA across various diseases, a critical gap exists in

Table 4: Effect of *p*-PBA on lipid profile in rats over the treatment period.

Parameters (Unit)	Treatment groups	
	NC (0.1% CMC)	<i>p</i> -PBA (2000 mg/kg)
Serum cholesterol (mg/dL)	95.10±2.40	92.13±3.77
Serum triglyceride (mg/dL)	72.94±2.44	70.43±3.51
Serum high-density lipoprotein (mg/dL)	60.39±2.86	62.12±2.24
Serum low-density lipoprotein (mg/dL)	49.24±2.92	52.01±2.46
Serum very low-density lipoprotein (mg/dL)	15.77±0.97	13.52±1.34

CMC: Carboxymethyl cellulose, *p*-PBA: *p*-propoxybenzoic acid, NC: Normal control

Table 5: Effect of *p*-PBA on complete blood count profile in rats over the treatment period.

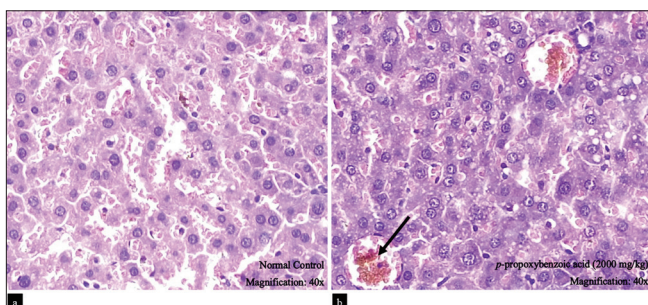
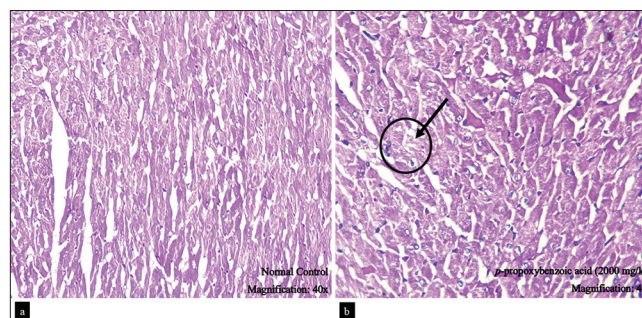
Parameters (Unit)	Treatment groups	
	NC (0.1% CMC)	<i>p</i> -PBA (2000 mg/kg)
Haemoglobin (g/dL)	10.72±0.34	11.32±0.21
Total red blood cells ($\times 10^{12}/L$)	7.29±0.17	70.43±3.51
Platelet count ($\times 10^{12}/L$)	217±3.42	292±5.92
White blood cells count ($\times 10^9/L$)	4.12±0.210	5.30±0.320
Haematocrit (%)	31.90±0.49	33.10±0.20
Monocytes (%)	2.33±0.19	2.57±0.14
Eosinophils (%)	2.10±0.20	2.25±0.17
Neutrophils (%)	15.90±1.86	16.80±1.78
Lymphocytes (%)	89.21±1.97	82.17±1.46
Mean corpuscular haemoglobin (FL)	52.21±0.72	52.91±0.36
Mean corpuscular haemoglobin concentration (g/dL)	31.90±0.17	33.59±0.14
Mean corpuscular volume (Pg)	15.46±0.20	18.23±0.11

CMC: Carboxymethyl cellulose, *p*-PBA: *p*-propoxybenzoic acid, NC: Normal control

Table 6: Effect of *p*-PBA on organ-to-body weight ratio in rats over the treatment period.

Organs	Organ-to-body weight ratio (%)	
	NC (0.1% CMC)	<i>p</i> -PBA (2000 mg/kg)
Heart	0.78±0.02	0.82±0.02
Liver	1.77±0.24	1.81±0.14
Right kidney	0.94±0.01	0.90±0.01

CMC: Carboxymethyl cellulose, *p*-PBA: *p*-propoxybenzoic acid, NC: Normal control

**Figure 1:** Histopathology of liver observed at $\times 40$ magnification (a) normal control group and (b) *p*-propoxybenzoic acid (2000 mg/kg) group (Black arrow indicates the presence of patchy necrosis).**Figure 2:** Histopathology of the heart observed at $\times 40$ magnification (a) normal control group and (b) *p*-propoxybenzoic acid (2000 mg/kg) group (black arrow indicates the presence of cardiac muscle damage).

our understanding of its potential toxicity and adverse effects (AEs). To address this aspect, we conducted an acute oral toxicity study following the OECD Guideline 425 procedure.^[8] This standardised approach is essential for assessing the acute toxicity of a substance, providing insights into the possible organ toxicity and submaximal lethal doses and establishing appropriate doses for subsequent toxicity studies and *in vivo* investigations. Female SD rats were considered experimental animals due to the higher sensitivity

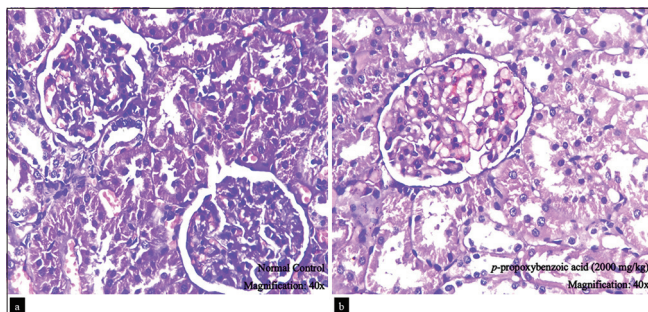


Figure 3: Histopathology of kidney observed at $\times 40$ magnification (a) normal control group and (b) *p*-propoxybenzoic acid (2000 mg/kg) group.

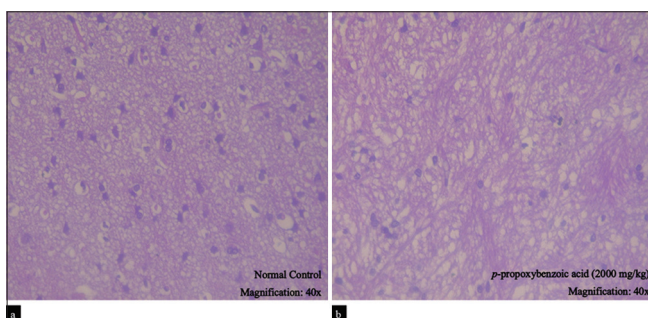


Figure 4: Histopathology of cerebellum observed at $\times 40$ magnification (a) normal control group and (b) *p*-propoxybenzoic acid (2000 mg/kg) group

of females in acute oral toxicity tests.^[15] We aimed to present an output that may determine a safe initial dose for future investigations, enhancing the understanding of the overall safety profile of *p*-PBA.

The sustained body weight stability in animals treated with *p*-PBA is indicative of the compound's minimal impact on overall health and metabolic processes during the acute exposure period.^[16] In addition, the absence of AEs and mortality in rats subjected to 2000 mg/kg *p*-PBA further underscores the safety profile of the compound at this dose level. Observed alterations such as increased respiration,^[17] sleeping tendencies^[18] and episodes of itching^[19] may provide contextual information suggesting a potential influence of *p*-PBA on certain physiological aspects.^[20] Despite these behavioural changes, there were no indications of critical abnormalities, including convulsions or comatose states, which were observed. It may state the overall benign nature of *p*-PBA at the administered dose. The absence of any alterations in serum renal parameters and lipid profile affirms the minimal impact of *p*-PBA on renal and lipid functions. This analysis of physiological and behavioural parameters collectively supports the contention that *p*-PBA exhibits a favourable safety profile at the investigated dose, laying a foundation for its continued exploration in pre-clinical and clinical studies. Histopathological analysis

of heart, kidney, liver and cerebellum tissues has not shown any serious indication of toxicity, suggesting a lack of AEs on the structural integrity of these vital organs. Notably, the histopathological examination of heart tissue revealed a minor presence of muscular damage following the administration of *p*-PBA. In the cerebellum, the histopathological analysis unveiled the presence of a loose network of neurons following the administration of *p*-PBA.

The study may provide a safety profile of *p*-PBA, which has garnered attention for its therapeutic potential against various diseases. By evaluating the acute effects in female SD rats, we have established a baseline for understanding the toxicity of *p*-PBA, elucidating its lack of AEs and mortality at 2000 mg/kg dose. Looking beyond safety considerations, our findings align with the broader therapeutic potential attributed to *p*-PBA. With established anti-diabetic properties^[5,7] and promising indications of anti-cancer activity from *in silico* and *in vitro* studies, *p*-PBA emerges as a multifaceted compound deserving of further exploration. The understanding of safety parameters obtained from this study may provide a roadmap for determining appropriate doses of *p*-PBA for extended toxicity studies. By addressing the gaps in the understanding of the safety and toxicity of *p*-PBA, our study provides insights into the scientific characterisation of this compound. However, the study focused on acute toxicity and may not capture potential long-term effects that could arise in sub-acute and chronic exposures. A more comprehensive approach, including sub-acute and chronic toxicity studies, is warranted to provide a thorough understanding of the impact of *p*-PBA over chronic treatment.

CONCLUSION

The study assessed the acute oral toxicity of *p*-PBA in female Sprague Dawley rats, following the OECD guideline 425 – up and down method. The findings demonstrate that 2000 mg/kg *p* PBA does not result in significant adverse events on body weight, behavioural patterns, serum parameters, lipid parameters or histopathological findings over a 14-day observation period. Overall, the results indicated a favourable acute safety profile in rats, which can be further investigated for sub-acute and chronic toxicity analysis. Additionally, the therapeutic potential of *p*-PBA can be explored.

Authors' contributions

KR conducted the study and drafted the manuscript. PT supervised the work.

Availability of data

Presented data within the manuscript are accessible on request.

The data presented in the manuscript is accessible upon request.

Ethical approval

The utilisation of Sprague-Dawley rats for the study was approved by the Institutional Animal Ethics Committee (IAEC) under the IAEC number RKCP/COI/RE/22/128.

Declaration of patient consent

Patient's consent was not required as there are no patients in this study.

Financial support and sponsorship

Nil.

Conflicts of interest

There are no conflicts of interest.

Use of artificial intelligence (AI)-assisted technology for manuscript preparation

The authors confirm that there was no use of artificial intelligence (AI)-assisted technology for assisting in the writing or editing of the manuscript and no images were manipulated using AI.

REFERENCES

- Shivhare MK, Singour PK, Chaurasiya PK, Pawar RS. *Trianthema portulacastrum* Linn. (Bishkhapra). *Pharmacogn Rev* 2012;6:132-40.
- Riaz M, Saleem A, Siddique S, Khan BA, Nur-e-Alam M, Shahzad-ul-Hussan S, *et al.* Phytochemistry of *Daphne oleoides*. *Nat Prod Res* 2016;30:880-97.
- Zhai X, Lenon GB, Xue CC, Li CG. *Euonymus alatus*: A review on its phytochemistry and antidiabetic activity. *Evid Based Complement Alternat Med* 2016;2016:9425714.
- Johnson EC, Ukpe RA, Etim EI, Umoh UF, Eseyin OA, Udoh AE, *et al.* *In vitro* antidiabetic, aphrodisiac and antimicrobial properties of para-propoxybenzoic acid isolated from *Acacia auriculiformis* A. Cunn Ex. Benth (*Fabaceae*) stem bark. *Trop J Pharm Res* 2022;20:613-20.
- Raval K, Tirgar P. *In-silico* and *in-vitro* evaluation of the anti-diabetic potential of p-propoxybenzoic acid. *Chettinad Health City Med J* 2023;12:39-44.
- Moon HE, Islam N, Ahn BR, Chowdhury SS, Sohn HS, Jung HA, *et al.* Protein tyrosine phosphatase 1B and α -glucosidase inhibitory Phlorotannins from edible brown algae, *Ecklonia stolonifera* and *Eisenia bicyclis*. *Biosci Biotechnol Biochem* 2011;75:1472-80.
- Raval KY, Tirgar PR. A pre-clinical study to investigate the

anti-diabetic potential of p-propoxybenzoic acid as a multi-target inhibitor in streptozotocin-nicotinamide induced type-2 diabetic rats. *J Diabetes Metab Disord* 2023;22:571-80.

- OECD. Test No. 425: Acute oral toxicity: Up-and-down procedure. Paris: Organisation for Economic Co-operation and Development; 2022. Available from: https://www.oecd-ilibrary.org/environment/test-no-425-acute-oral-toxicity-up-and-down-procedure_9789264071049-en [Last accessed on 2023 Dec 02].
- Secher N, Malte CL, Tønnesen E, Østergaard L, Granfeldt A. Comparing anesthesia with isoflurane and fentanyl/fluanisone/midazolam in a rat model of cardiac arrest. *J Appl Physiol* (1985) 2017;123:867-75.
- Parasuraman S, Raveendran R, Kesavan R. Blood sample collection in small laboratory animals. *J Pharmacol Pharmacother* 2010;1:87-93.
- Kozan R, Şare M, Yılmaz TU, Yüksel S, Şeneş M, Çaycı AB, *et al.* Effectiveness of new parameters in the evaluation of pneumoperitoneum-related acute kidney injury in rats. *Turk J Med Sci* 2018;48:1278-84.
- Khalifa MM, Bakr AG, Osman AT. Protective effects of phloridzin against methotrexate-induced liver toxicity in rats. *Biomed Pharmacother* 2017;95:529-35.
- Procópio IM, Pereira-Sampaio MA, Costa WS, Sampaio FJ, De Souza DB. Histomorphometric comparison of the corpus cavernosum of rats submitted to euthanasia with ketamine and xylazine or isoflurane. *Acta Cir Bras* 2021;36:e361103.
- Kluxen FM. Scatter plotting as a simple tool to analyse relative organ to body weight in toxicological bioassays. *Arch Toxicol* 2019;93:2409-20.
- Lipnick RL, Cotruvo JA, Hill RN, Bruce RD, Stitzel KA, Walker AP, *et al.* Comparison of the up-and-down, conventional LD50, and fixed-dose acute toxicity procedures. *Food Chem Toxicol* 1995;33:223-31.
- Sherk VD, Jackman MR, Higgins JA, Giles ED, Foright RM, Presby DM, *et al.* Impact of exercise and activity on weight regain and musculoskeletal health post-ovariectomy. *Med Sci Sports Exerc* 2019;51:2465-73.
- Vuralli D, Wattiez AS, Russo AF, Bolay H. Behavioral and cognitive animal models in headache research. *J Headache Pain* 2019;20:11.
- Santangeli O, Lehtikuja H, Palomäki E, Wigren HK, Paunio T, Porkka-Heiskanen T. Sleep and behavior in cross-fostering rats: Developmental and sex aspects. *Sleep* 2016;39:2211-21.
- Spradley JM, Davoodi A, Carstens MI, Carstens E. Effects of acute stressors on itch-and pain-related behaviours in rats. *Pain* 2012;153:1890-7.
- Grigoruță M, Martínez-Martínez A, Dagda RY, Dagda RK. Psychological stress phenocopies brain mitochondrial dysfunction and motor deficits as observed in a parkinsonian rat model. *Mol Neurobiol* 2020;57:1781-98.

How to cite this article: Raval K, Tirgar P. Acute oral toxicity evaluation of p-propoxybenzoic acid in Sprague-Dawley rats according to OECD guideline 425 – Up-and-down method. *Indian J Physiol Pharmacol*. doi: 10.25259/IJPP_21_2024