

## Case Report

# Hydroxychloroquine-induced reversible keratopathy in a coronavirus disease 2019 patient: A case report

Rajat Pramod Khanavkar<sup>1</sup>, Aditi Kanade-Sable<sup>1</sup>, Saleem B. Tamboli<sup>1</sup>, Abdul Hannan<sup>1</sup>

<sup>1</sup>Department of Pharmacology, Grant Government Medical College and Sir J.J Group of Hospitals, Mumbai, Maharashtra, India.

### \*Corresponding author:

Aditi Kanade-Sable,  
Department of Pharmacology,  
Grant Government Medical  
College and Sir J.J Group  
of Hospitals, Mumbai,  
Maharashtra, India.

kanadeaditi8@gmail.com

Received: 08 February 2024  
Accepted: 12 August 2024  
Epub Ahead of Print: 11 September 2024  
Published: 04 October 2024

### DOI

10.25259/IJPP\_52\_2024

### Quick Response Code:



## ABSTRACT

The respiratory tract infection known as coronavirus disease 2019 (COVID-19) was first discovered in Wuhan, China, in December 2019. This disease causes symptoms such as fever, chills, cough and shortness of breath. Hydroxychloroquine (HCQ) was used for treatment as well as prophylaxis of mild cases of COVID-19 (postulated mechanism of viral replication reduction). HCQ has known safety in malaria and autoimmune diseases. However, its safety in COVID-19 is not proven. The patient, in this case, was detected COVID-19 reverse transcription polymerase chain reaction positive and was started with Tab. HCQ, along with home quarantine. On day 2, she developed blurred vision and reading difficulty. After obtaining an ophthalmologist referral, no change was made in the treatment. Once 7 days of Tab. HCQ treatment was over, and the vision resolved spontaneously. Cardiac side effects of HCQ have always been a focus, but ocular manifestations also need to be considered. HCQ-induced vortex keratopathy is generally seen after 2 weeks, but this COVID-19 patient developed it within the first 2 days, which makes this case unusual.

**Keywords:** Hydroxychloroquine, Reversible, Keratopathy, Coronavirus disease 2019

## INTRODUCTION

The respiratory tract infection known as coronavirus disease 2019 (COVID-19) was first discovered in Wuhan, China, in December 2019. This disease causes symptoms such as fever, chills, cough and shortness of breath.<sup>[1]</sup> COVID-19 infection is categorised as asymptomatic, mild, moderate and severe. Asymptomatic disease is accidentally identified without additional signs or symptoms. Hydroxychloroquine (HCQ) was used for treatment as well as prophylaxis of mild COVID-19 (postulated mechanism of viral replication reduction).<sup>[2,3]</sup> HCQ has known safety in malaria and autoimmune diseases. However, its safety in COVID-19 is not proven. COVID-19 patients, especially those with advanced age and comorbidities, are more vulnerable to adverse events such as gastrointestinal (most common), skin rash, headache, dizziness and ocular toxicity. Serious side effects like cardiac arrhythmias are rare.

## CASE REPORT

A 52-year-old female, scheduled for renal calculi removal, was detected with COVID-19 reverse transcription polymerase chain reaction (RT-PCR) positive on 23<sup>rd</sup> February 2021 before her surgery. Hence, the surgery was postponed. As the patient was asymptomatic with stable vitals and no known comorbidities, she was advised home quarantine for 2 weeks as per ICMR treatment

guidelines for COVID-19. She was advised Tab. HCQ 200 mg (2 tablets BD on day 1 followed by 1 tab. BD for next 5 days) along with Tab. Zinc, Tab. Vit. C, Tab. Vit. D and Tab. Paracetamol (if needed). However, on Day 2, the patient developed sudden blurred vision and reading difficulty. Patient had no complaints of loss of colour vision, central blind spots, halos around light and photophobia. She did not have a history of using reading glasses. The severity of symptoms remained the same for the next 4–5 days. Once 7 days of Tab. HCQ treatment was over, and the vision resolved spontaneously.

### Methodology

A comprehensive patient examination was done, and all significant medical records were reviewed. This case was assessed as per the Pharmacovigilance Program of India. AMC report no. is GGMC/2021/Feb/07.

### Diagnostic assessment

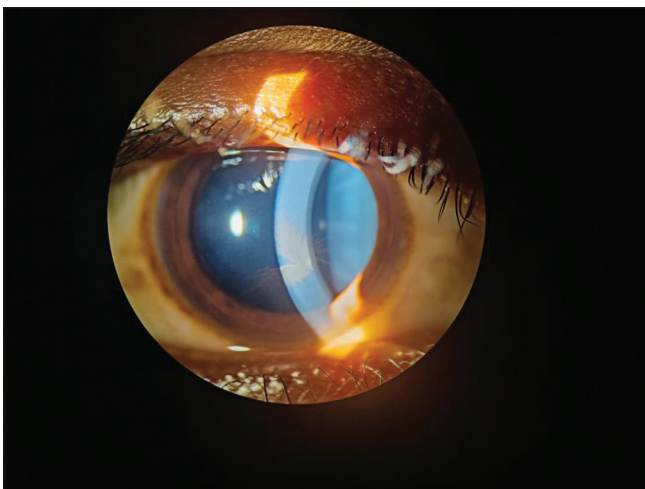
Before surgery, RT-PCR was done on 23<sup>rd</sup> February 2021 and was positive for COVID-19 infection. A slit-lamp examination was performed by an ophthalmologist and showed vortex keratopathy [Figure 1].

### Treatment and outcome

After obtaining an ophthalmology referral, the treatment regimen was continued as the reaction was mild and reversible. Once the 7-day treatment regimen with Tab. HCQ got over, vision resolved spontaneously.

## DISCUSSION

HCQ is commonly used to treat malaria and rheumatologic conditions such as rheumatoid arthritis and systemic lupus



**Figure 1:** Slit-lamp examination of the patient showing vortex keratopathy.

erythematous. It grew well-known during the COVID-19 pandemic for its experimental usage in treating coronavirus infection.<sup>[4]</sup> Many systemic medications cause alterations in the corneal epithelium, which are characterised by deposits that might appear as diffuse corneal haze, punctate keratopathy, crystalline precipitates or vortex keratopathy (also known as whorled or verticillate keratopathy). A few examples are amiodarone, tamoxifen, non-steroidal anti-inflammatory drugs, aminoglycosides, gold salts, etc.<sup>[5]</sup> Although the exact pathophysiology of HCQ-induced vortex keratopathy is unknown, it is generally agreed that intra-lysosomal lipid accumulation in the corneal epithelium occurs as a result of either drug-lipid complex formation or lysosomal phospholipase inhibition.<sup>[6]</sup> On 28 March 2020, the Food and Drug Association (FDA) approved the chloroquine and HCQ regimen for COVID-19 emergency usage based on the regimen's early testing results for treating coronavirus infection. However, no therapeutic benefit of HCQ treatment in COVID-19 patients was demonstrated by the two largest randomised controlled trial data to date. The FDA consequently terminated this regimen's emergency use authorisation.<sup>[7-10]</sup>

### Patient perspective

I have experienced blurred vision and reading difficulty since day 2 of starting COVID-19 treatment. I consulted my treating physician for my problem. After a few additional tests, I was made aware of the cause of my symptoms and their severity. I completed the treatment regimen as advised, and the symptoms resolved within a few days.

## CONCLUSION

Cardiac side effects of HCQ have always been a focus, but ocular manifestations also need to be considered. HCQ-induced vortex keratopathy is generally seen after 2 weeks, but this COVID-19 patient developed it within the first 2 days, which makes this case unusual. With the growing clinical utility of HCQ, vortex keratopathy could be observed more often. In the current patient, vortex keratopathy is unlikely to be caused by the disease or other drugs, and the response to the withdrawal of the drug was clinically reasonable. Our study is supported by temporal association and biological plausibility. According to World Health Organisation-Uppsala Monitoring Centre causality assessment is PROBABLE. In such cases, the goal should be to perform a baseline ocular examination if and whenever possible and inform patients about benefits and complications before treatment. Ophthalmologist consultation should be taken for early detection of toxicity if any abnormal visual symptoms develop. Primary care physicians should take a comprehensive history and be cautious while prescribing HCQ in patients with ocular diseases and or age >50.

**Ethical approval**

The Institutional Review Board approval is not required.

**Declaration of patient consent**

The authors certify that they have obtained all appropriate patient consent.

**Financial support and sponsorship**

Nil.

**Conflicts of interest**

There are no conflicts of interest.

**Use of artificial intelligence (AI)-assisted technology for manuscript preparation**

The authors confirm that there was no use of artificial intelligence (AI)-assisted technology for assisting in the writing or editing of the manuscript and no images were manipulated using AI.

**REFERENCES**

1. Wolff D, Nee S, Hickey NS, Marschollek M. Risk factors for Covid-19 severity and fatality: A structured literature review. *Infection* 2021;49:15-28.
2. Yao X, Ye F, Zhang M, Cui C, Huang B, Niu P, *et al.* *In vitro* antiviral activity and projection of optimized dosing design of hydroxychloroquine for the treatment of severe acute respiratory syndrome coronavirus 2 (SARS-CoV-2). *Clin Infect Dis* 2020;71:732-9.
3. Liu J, Cao R, Xu M, Wang X, Zhang H, Hu H, *et al.* Hydroxychloroquine, a less toxic derivative of chloroquine, is effective in inhibiting SARS-CoV-2 infection *in vitro*. *Cell Discov* 2020;6:16.
4. Stokkermans TJ, Falkowitz DM, Trichonas G. Chloroquine and hydroxychloroquine toxicity. In: StatPearls. Treasure Island, FL: Stat Pearls Publishing; 2024. Available from: <https://www.ncbi.nlm.nih.gov/books/nbk537086> [Last accessed on 2024 Jan 31].
5. Raizman MB, Hamrah P, Holland EJ, Kim T, Mah FS, Rapuano CJ, *et al.* Drug-induced corneal epithelial changes. *Surv Ophthalmol* 2017;62:286-301.
6. Savage DE, Plotnik R, Wozniak RA. Short-term, high-dose hydroxychloroquine corneal toxicity. *Am J Ophthalmol Case Rep* 2020;18:100713.
7. Saghir SA, AlGabri NA, Alagawany MM, Attia YA, Alyileili SR, Elnesr SS, *et al.* Chloroquine and hydroxychloroquine for the prevention and treatment of COVID-19: A fiction, hope or hype? An updated review. *Ther Clin Risk Manag* 2021;17:371-87.
8. RECOVERY Collaborative Group, Horby P, Mafham M, Linsell L, Bell JL, Staplin N, *et al.* Effect of hydroxychloroquine in hospitalized patients with covid-19. *N Engl J Med* 2020;383:2030-40.
9. Skipper CP, Pastick KA, Engen NW, Bangdiwala AS, Abassi M, Lofgren SM, *et al.* Hydroxychloroquine in nonhospitalized adults with early COVID-19: A randomized trial. *Ann Intern Med* 2020;173:623-31.
10. WHO Solidarity Trial Consortium, Pan H, Peto R, Henao-Restrepo AM, Preziosi MP, Sathiyamoorthy V, *et al.* Repurposed antiviral drugs for covid-19 - Interim WHO solidarity trial results. *N Engl J Med* 2021;384:497-511.

**How to cite this article:** Khanavkar RP, Kanade-Sable A, Tamboli SB, Hannan A. Hydroxychloroquine-induced reversible keratopathy in a coronavirus disease 2019 patient: A case report. *Indian J Physiol Pharmacol.* 2024;68:243-5. doi: 10.25259/IJPP\_52\_2024